

Acute esophageal necrosis in a patient with multiple comorbidity

Victor Gonzalez Carrera, Sergio Vazquez Rodriguez, Enrique Gonzalez de la Ballina Gonzalez, Jose Luis Ulla Rocha

Pontevedra Hospital, Pontevedra, Spain

We report a case of a male, aged 84, with type 2 diabetes, arterial hypertension, ischemic cardiomyopathy and chronic renal disease. We placed a percutaneous endoscopic gastrostomy one year ago, and we did not notice any injuries in the esophagus. We performed an urgent gastroscopy because the patient had an episode of coffee-ground vomit. In the distal third of the esophagus the mucosa had a necrotic aspect and it affected the complete circumference (Fig. 1A) but the gastroesophageal junction was not affected (Fig. 1B).

Acute esophageal necrosis (AEN), also designated as black esophagus, is a rare disorder. An association between AEN, malnutrition and debilitated state suggests an overall reduction in the mucosal defense mechanism of the esophagus [1]. The diagnosis is reached endoscopically, whereas biopsy material may be obtained for definitive histologic confirmation, but it is not required [2], because of the incremented risk of iatrogenic perforation. In the above case we showed the typical findings of circumferential black discoloration of the distal esophagus with proximal extension ending sharply at the gastroesophageal junction. Differential diagnosis of black esophagus includes acute necrotizing esophagitis, infectious causes, malignant melanoma, acanthosis nigricans, pseudomelanosis, melanosis of the esophagus, exogenous dye ingestion and lye ingestion; the differential diagnosis can be made with biopsy or brush cytology [3].

Treatment includes nil-per-os, volemic resuscitation and intravenous proton pump inhibitor, whereas the use of antibiotics in black esophagus remains controversial [4].

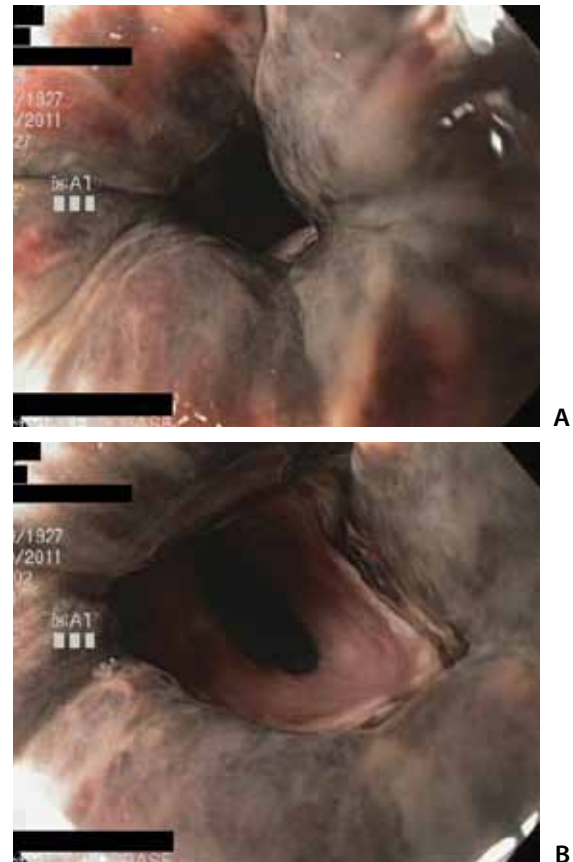


Figure 1 Circumferential necrosis of the esophageal mucosa (A) with normal gastroesophageal junction (B)

References

1. Gurvits GE. Black esophagus: Acute esophageal necrosis syndrome. *World J Gastroenterol* 2010;**16**:3219-32125.
2. Singh D, Singh R, Laya AS. Acute esophageal necrosis: a case series of five patients presenting with "Black esophagus". *Indian J Gastroenterol* 2011;**30**:41-45.
3. Gurvits GE, Robilotti JG. Isolated proximal black esophagus: etiology and the role of tissue biopsy. *Gastrointest Endosc* 2010;**71**:658.
4. Gurvits GE. Management of acute esophageal necrosis. *J Thorac Cardiovasc Surg* 2011;**142**:955.

Department of Gastroenterology, Pontevedra Hospital, Pontevedra, Spain

Conflict of Interest: None

Correspondence to: Victor Gonzalez Carrera, MD, Mourente Avenue, 36071 Pontevedra, Spain, Tel: 0034 986800000, Fax: 0034 986807052, e-mail: vgcarrera@yahoo.es

Received 17 January 2012; accepted 23 January 2012