

Upper esophageal ring due to gastric heterotopia

Konstantinos H. Katsanos, Dimitrios E. Sigounas, Dimitrios K. Christodoulou, Epameinondas V. Tsianos

University Hospital of Ioannina, Greece

Heterotopic gastric mucosa (HGM) can occur in the fore-mid- and hindgut and, conceivably, at any of their derivatives. The origin of HGM is either heterotopic (congenital) or metaplastic (acquired). The reported incidence of HGM in the endoscopic literature ranges from 0.29-10% but an incidence of up to 70% has been reported in autopsy studies. Heterotopic gastric mucosa patches have been reported to occur anywhere along the gastrointestinal tract from mouth to anus [1].

The patient presented herein complained of dysphagia and was diagnosed as having upper esophageal ring (Fig. 1). The scope passed the ring easily and subsequent biopsies confirmed gastric heterotopia *Helicobacter pylori*-negative. The patient was successfully treated with proton pump inhibitors.

HGM in the esophagus is thought to arise from gastric precursor cells that remain after incomplete replacement of the original stratified columnar epithelium lining the embryonic esophagus by stratified squamous epithelium. Diagnosis of HGM is often difficult and requires experience and a high degree of suspicion. Interestingly, there seems to be a clear connection of HGM with laryngoesophageal reflux and globus in some patients. At endoscopy, the HGM appears as a mainly flat or slightly raised, well circumscribed red-orange salmon-colored patch. This is mainly a solitary patch but can be multiple, measuring from a few millimeters to several centimeters. Complications of HGM patches include dysphagia, upper gastrointestinal bleeding, stricture [2] and fistula formation, upper esophageal ring and adenocarcinoma. Of interest, upper esophageal rings may coexist with Barrett's esophagus [3].

This case corresponds to type III HGM according to the new clinicopathologic classification of esophageal HGM [4],

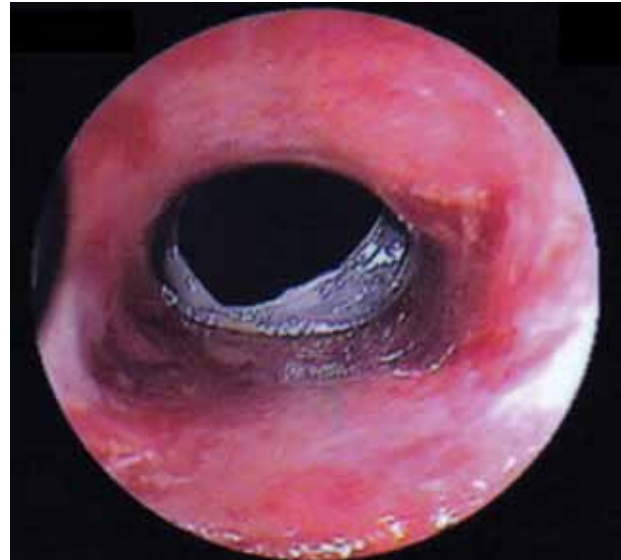


Figure 1 Upper esophageal ring due to gastric heterotopia

i.e., asymptomatic patients (HGM I), patients who complain of dysphagia, odynophagia, hoarseness and coughing without further morphologic findings (HGM II), patients symptomatic due to morphologic changes such as esophageal strictures, webs, or esophagotracheal fistula (HGM III), patients with malignant transformation via dysplasia (intraepithelial neoplasia, HGM IV) and patients with cervical esophageal adenocarcinoma (HGM V). Consequently, the need for endoscopic surveillance is of importance in these HGM patients.

References

1. Borhan-Manesh F, Farnum JB. Incidence of heterotopic gastric mucosa in the upper oesophagus. *Gut* 1991;32:968-972.
2. Johnson AC, Lester PD, Johnson S, Sudarsanam D, Dunn D. Esophagogastric ring: why and when we see it, and what it implies: a radiologic-pathologic correlation. *South Med J* 1992;85:946-952.
3. Weaver GA. Upper esophageal web due to a ring formed by a squamocolumnar junction with ectopic gastric mucosa. *Dig Dis Sci* 1979;24:959-963.
4. von Rahden BHA, Stein HJ, Becker K, Liebermann-Meffert D, Siewert JR. Heterotopic Gastric mucosa of the esophagus: literature-review and proposal of a clinicopathologic classification heterotropic gastric mucosa of the esophagus. *Am J Gastroenterol* 2004;99:543-551.

1st Department of Internal Medicine & Hepato-Gastroenterology Unit, University Hospital of Ioannina, Greece

Conflict of Interest: None

Correspondence to: Prof. Epameinondas V. Tsianos, MD, PhD, AGAF, Professor of Internal Medicine, Department of Internal Medicine, Medical School, University of Ioannina, Leoforos Panepistimiou, 45 110 Ioannina, Greece Tel: +30 26510 07501, Fax: +30 26510 07016, e-mail: etsianos@uoi.gr

Received 7 December 2011; accepted 2 January 2012