

Tunnel-free peroral endoscopic myotomy reduces procedural time and maintains efficacy in Zenker's diverticulum

Georgios Mavrogenis^a, Maria Zachou^a, Ioannis Tsevgas^a, Konstantinos Markoglou^a,
Dimitrios Zachariadis^a, Anna Spanomanoli^b, Marinos Chatzis^b, Fateh Bazerbachi^c

Mediterraneo Hospital, Athens, Greece; St. Cloud Hospital, Minnesota, USA

Abstract

Background Peroral endoscopic myotomy (Z-POEM) is an effective treatment for Zenker's diverticulum (ZD), but procedural time and safety vary based on technique. Modified Z-POEM approaches incorporating fewer submucosal tunnels may offer advantages.

Methods In this retrospective, single-center study, we compared outcomes among 20 patients with ZD undergoing standard Z-POEM (2 tunnels), single-tunnel Z-POEM (ST Z-POEM), or tunnel-free Z-POEM (TF Z-POEM). All procedures included mucosotomy over the septum and deep extension of myotomy into the esophagus (2 cm). Primary endpoints were procedural time, clinical success, and adverse events.

Results Patients had a mean age of 67.3 ± 12.2 years, and 70% presented with respiratory symptoms. Mean procedure times were 45 min (standard Z-POEM), 33 min (ST Z-POEM), and 30 min (TF Z-POEM), with a statistically significant difference between the standard and TF Z-POEM groups ($P=0.014$). Technical success was 100%, and the mean hospital stay was 1.3 ± 1.3 days. One adverse event (5%) occurred. Clinical success, defined as improvement in dysphagia score (3 to 0.05, $P<0.001$) and resolution of respiratory symptoms, was achieved in all patients.

Conclusions In this study, modified Z-POEM techniques utilizing single-tunnel or tunnel-free approaches, combined with over-the-septum mucosotomy and deep esophageal myotomy (2 cm), demonstrated feasibility, safety and a significantly shorter procedural time compared to standard Z-POEM. These findings suggest potential benefits for ZD treatment, warranting further investigation in larger prospective studies.

Keywords Zenker's diverticulum, peroral endoscopic myotomy, tunnel-free technique, single-tunnel technique, septotomy

Ann Gastroenterol 2024; 37 (XX): 1-5

An earlier version of this work was presented at DDW 2024 with title: Tunnel-free peroral endoscopic myotomy for Zenker's diverticulum (Z-POEM) shortens significantly the duration of the procedure (4012052)

Conflict of Interest: None

Correspondence to: Georgios Mavrogenis, Director of Hybrid Interventional Endoscopy, Mediterraneo Hospital, Ilias 8-12, 16675 Glyfada, Greece, e-mail: mavrogenis@gmail.com

Received 14 February 2024; accepted 23 May 2024; published online 12 July 2024

DOI: <https://doi.org/10.20524/aog.2024.0902>

This is an open access journal, and articles are distributed under the terms of the Creative Commons Attribution-NonCommercial-ShareAlike 4.0 License, which allows others to remix, tweak, and build upon the work non-commercially, as long as appropriate credit is given and the new creations are licensed under the identical terms

Introduction

The endoscopic management of Zenker's diverticulum (ZD) has benefited from the introduction of the peroral myotomy approach, which offers several advantages over standard flexible endoscopic septotomy. In this context, Zenker's peroral endoscopic myotomy (Z-POEM) ensures complete identification of structures deep in the submucosal space, immediate recognition of the targeted muscular septum, and limitation of the therapy to the submucosal space, which may in turn decrease the risk of perforation, leak and ensuing infections. The original technique was described by Li *et al* in 2016 [1], and includes tunneling into the hypopharynx a few centimeters proximally to the septum, followed by double tunneling around the septum. Myotomy is then performed and the opening is closed with clips.

Several streamlining modifications of this approach were then adopted, to shorten and facilitate the intervention. The

first change was to pursue the mucosotomy over the septum, instead of starting the tunnel more proximally [2-4]. This approach has 2 benefits. First, the exposure of the septum is easier and faster. Second, placement of clips in a zipper fashion over the septum is very convenient. In 2023, the single-tunnel technique was introduced (ST Z-POEM) [5] (Fig. 1), in which a standard diverticular tunnel is made and then a submucosal cushion is maintained on the esophageal side. This approach may be advantageous when conventional tunneling is challenging because of space limitations or preceding fibrosis (e.g., symptom recurrence after surgical or endoscopic management).

When implementing this modification, we appreciated that tunneling could be replaced by submucosal cushions without compromising septum exposure and subsequent myotomy. Therefore, what followed was the advent of the tunnel-free technique (TF Z-POEM) in both sides of the septum [6,7] (Fig. 2). In this most recent modification, 2 submucosal cushions are created on both sides of the septum, followed by direct myotomy. In this way, the procedure became easier and shorter without compromising the main concept of Z-POEM. The aim of this study was to retrospectively review a series of Z-POEM cases to describe the feasibility and efficacy, as well as the technical and outcome details of these different iterations of the Z-POEM procedure.

Patients and methods

The study was granted approval by the Mediterraneo Hospital Institutional Review Board. All Z-POEM cases performed at the Mediterraneo Hospital, Athens, Greece between January 2019 and December 2023 were entered into a prospectively maintained database and analyzed retrospectively. All procedures were performed by a single operator with significant experience in third-space endoscopic procedures (>150 cases), but without experience in standard endoscopic septotomy of ZD. The diagnosis of ZD was confirmed by means of gastroscopy with a cap and barium study. Z-POEM technique iterations followed an era progression: from 2019-2021 all cases were performed with the classic technique; from 2021-2022 with ST Z-POEM; and from 2022-2023 with TF Z-POEM. Treatment indication was determined by the presence of dysphagia to liquids and/or solids, quantified using the Dakkak and Bennett score (0: no dysphagia; 1: dysphagia to solids; 2: dysphagia to semisolids; 3: dysphagia to liquids; and 4: complete dysphagia) [8]. Further recorded symptoms that motivated an endoscopic treatment included weight loss and recurrent secondary respiratory complications. Treatment was contraindicated if a compromised medical status precluded

^aUnit of Hybrid Interventional Endoscopy, Department of Gastroenterology, Mediterraneo Hospital, Athens, Greece (Georgios Mavrogenis, Maria Zachou, Ioannis Tsevas, Konstantinos Markoglou, Dimitrios Zachariadis); ^bDepartment of Anesthesiology, Mediterraneo Hospital, Athens, Greece (Anna Spanomanoli, Marinos Chatzis); ^cCentraCare, Interventional Endoscopy Program, St. Cloud Hospital, St Cloud, Minnesota, USA (Fateh Bazerbachi)

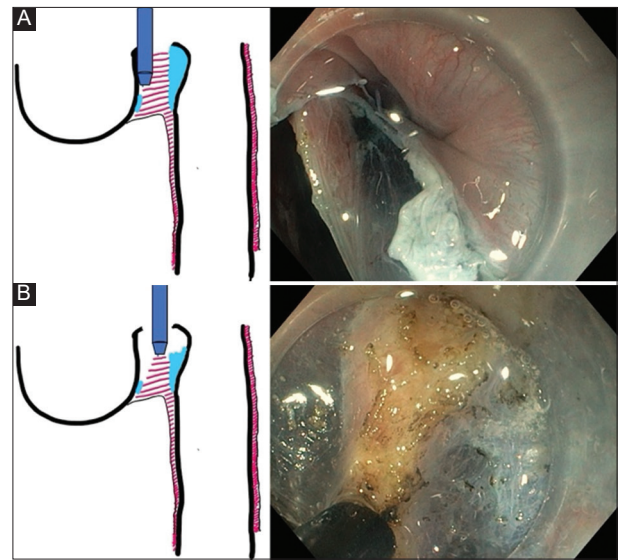


Figure 1 Single tunnel Zenker's peroral endoscopic myotomy. (A) Creation of a tunnel at the diverticular site and of a submucosal cushion on the esophageal side. (B) Myotomy

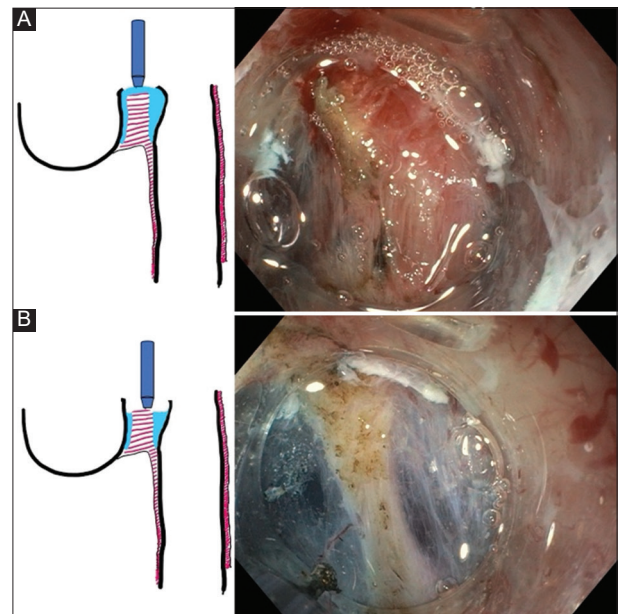


Figure 2 Tunnel free Zenker's peroral endoscopic myotomy. (A) Submucosal cushions on both sides of the septum. (B) Myotomy

general anesthesia, or if informed consent could not be obtained.

Procedure technique

All patients provided written informed consent prior to the intervention. Procedures were conducted in the endoscopy department with patients in either the left lateral position (first 2 cases) or a supine position (subsequent cases) under general

anesthesia. A high-definition gastroscope (GIF-185, GIF-1TH 190, or EZ-1500, Olympus, Tokyo, Japan) fitted with a clear cap and utilizing carbon dioxide insufflation was employed. Saline was used for diverticulum cleaning with suction applied for residue removal, or basket extraction if necessary. A hydroxyethyl starch and indigo carmine mixture was injected submucosally above the septum. A 15-mm mucosal incision was created at the septal apex using a Flush Knife BTs 1.5 mm (Fujifilm, Tokyo, Japan) in Endocut Q mode E2 (ERBE VIO 3, Tubingen, Germany). Submucosal areas on either side of the septum were lifted using indigo carmine-infused normal saline 0.9%.

Procedural technique varied by group: (a) standard Z-POEM: bilateral submucosal tunneling was performed prior to myotomy; (b) ST Z-POEM: unilateral tunneling (diverticular side) was performed, preserving an esophageal-side submucosal cushion; and (c) TF Z-POEM: no tunneling; submucosal cushions maintained bilaterally by repeated knife injections to minimize mucosal injury.

In all groups, septal transection was performed using an Endocut Q mode alternating with Spray Coag mode (E3) for superior hemostasis. A 2-cm esophageal extension of the myotomy was performed to reduce recurrence risk, in contrast to the standard 1-cm extension [9,10]. Coagulation forceps (FD-410 LR, Olympus) were used to manage incidental bleeding uncontrolled by the knife. The pouch was inspected for remnant septal muscle fibers prior to endoscopic closure. Reopenable 11-16-mm clips were used in a zippered fashion for closure. A final endoscopic esophageal pass confirmed myotomy depth (proximal esophageal blue discoloration from injectate underneath), lack of transmucosal injury, and patency.

The post-procedure protocol included overnight observation, nil *per os* status, and either esophagram or cervical computed tomography with oral contrast to rule out leaks. Patients progressed from a 1-week liquid diet to a 2-week soft diet. Broad-spectrum antibiotics were administered prophylactically for 7 days.

Follow up and study outcomes

At 2 months post-procedure, follow-up endoscopy was performed for clip removal and to assess for residual mucosal flaps. Subsequent patient contact occurred via phone at 6-month intervals through January 2024 to reevaluate dysphagia using the Dakkak and Bennet score.

The duration of the procedure was measured starting from the first submucosal injection over the septum up to the placement of the last clip. Technical success was defined as complete execution of the procedure. Clinical success was defined as complete or near-complete symptom resolution (Dakkak and Bennet score of 0 or 1), without requiring additional endoscopic or surgical intervention during follow up. For patients exhibiting mild postprocedural dysphagia (score 1), clinical success required complete dysphagia resolution (score 0). Adverse events were documented and

graded according to the American Society for Gastrointestinal Endoscopy lexicon [11].

Statistical analysis

The statistical analysis was carried out using SPSS 29.0 for Macintosh. Descriptive statistics employed means (\pm standard deviation) for normally distributed data, and medians (interquartile range) for non-normal distributions. Categorical data were represented as number (percentage). Median procedural durations across groups were compared using the Kruskal-Wallis test. Pairwise Mann-Whitney tests with Bonferroni correction were applied to identify stochastic dominance relationships. Pre- and post-treatment dysphagia scores were compared via paired *t*-tests. Statistical significance was determined by P-values <0.05 .

Results

This study included 20 patients (8 women) with ZD (mean age 67 ± 12.2 years) (Table 1). Patients underwent standard Z-POEM (n=5), ST Z-POEM (n=5), or TF Z-POEM (n=10). Only 1 patient had prior surgical treatment for ZD (standard Z-POEM group, case #5). Preprocedural assessment indicated a mean dysphagia score of 3 ± 1.3 , with 70% (14/20) of patients experiencing respiratory symptoms. Mean ZD size was 3 ± 1.1 cm. Mean procedure time across all groups was 34 ± 8.6 min (Table 2). Technical success was achieved in all cases, with a mean hospital stay of 1.3 ± 1.3 days. One adverse event (5%) occurred: a patient developed aspiration pneumonia during hospitalization due to postprocedural obstruction of the esophagus by clips (Patient #3, Standard Z-POEM group). The clips were repositioned endoscopically on day 2 after the procedure; the patient had an uneventful recovery with antibiotics, and was discharged on postoperative day 7. Since that case, the patency of the esophagus has been systematically checked after each procedure.

Clinical success was demonstrated by a significant decrease in the mean dysphagia score from 3.1 ± 1.3 to 0.05 ± 0.2 ($P<0.001$), and the resolution of respiratory symptoms in all cases. During a mean follow-up of 18.5 ± 9.3 months, no recurrence or residual mucosal septum was observed.

Procedure duration per group.

The median procedure duration per group was as follows: 45 min (range 30-50) for standard Z-POEM, 33 min (range 29-40) for ST Z-POEM, and 30 min (range 18-43) for TF Z-POEM. Differences in duration were statistically different between the first and last group ($P=0.014$) (Fig. 3).

Table 1 Baseline characteristics of 20 patients who underwent Zenker's peroral endoscopic myotomy (Z-POEM)

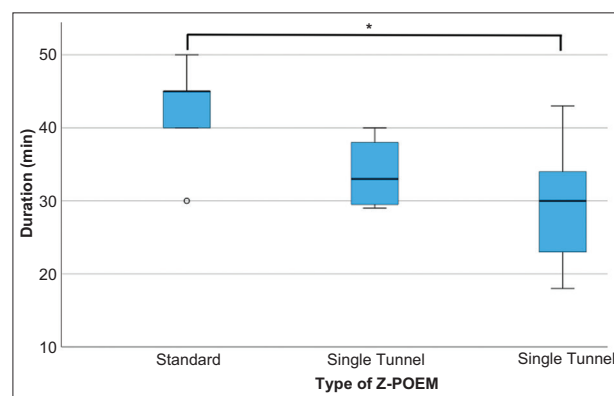
| Characteristics | Value |
|---------------------------|------------|
| Age, years, mean±SD | 67.25±12.2 |
| Women, % (n) | 40% (8) |
| ASA score, mean±SD | 1.65±0.58 |
| Prior intervention | 5% (1) |
| Size of ZD, cm, mean±SD | 3±1.12 |
| Z-POEM with 2 tunnels (n) | 5 |
| Single tunnel Z-POEM (n) | 5 |
| Tunnel-free Z-POEM (n) | 10 |

ASA, American Society of Anesthesiologists; SD, standard deviation

Table 2 Technical and clinical outcomes of Zenker's peroral endoscopic myotomy (Z-POEM)

| Outcomes | Value |
|---|----------------------|
| Technical success, % (n) | 100 (20/20) |
| Clinical success, % (n) | 100 (20/20) |
| Procedural time, median [range] | |
| Standard Z-POEM | 45 min (range 30-50) |
| Single Tunnel Z-POEM | 33 min (range 29-40) |
| Tunnel-free Z-POEM | 30 min (range 18-43) |
| Days of hospitalization, mean±SD | 1.35±1.34 |
| Post-procedure follow-up, days, mean±SD | 18.5±9.3 |
| Preprocedural dysphagia score, mean±SD | 3±1.3 |
| Postprocedural dysphagia score, mean±SD | 0.05±0.22 |
| Adverse events, % (n) | 5% (1) |

SD, standard deviation

**Figure 3** Box plots of the median duration of the procedure among groups. The median duration of Z-POEM was significantly shorter in the tunnel-free Z-POEM group compared to the standard Z-POEM group Z-POEM, Zenker's peroral endoscopic myotomy

Discussion

This case series demonstrates the feasibility, safety and efficacy of modified Z-POEM techniques incorporating direct

mucosotomy over the septum, with either a single-tunnel or a tunnel-free approach. Though our sample size was limited, these techniques achieved high success rates and reduced procedural times compared to previously reported findings. The current literature indicates that standard Z-POEM procedures in tertiary centers typically require 45-60 min [9,10,12], with 1-2 days mean hospitalization and a low risk (<7%) of conservatively managed side effects (bleeding, mucosal injury). Long-term clinical success rates for Z-POEM exceed 94%.

Our study findings align with Steinway *et al* [12] in demonstrating a 45-min procedural time for standard Z-POEM (mucosotomy over the septum, 2 tunnels). Notably, we demonstrate that omitting 1 or both tunnels, combined with direct incision over the septum, significantly reduces the procedural time. The ST Z-POEM group had a mean procedural time of 33 min, while the TF Z-POEM group achieved an even shorter duration of 30 min. A shorter procedural time presents several advantages, including enhanced suitability for elderly and frail patients and a potential reduction in overall procedural costs. Furthermore, these modifications may increase the attractiveness of Z-POEM compared to alternatives such as direct endoscopic septotomy, potentially broadening accessibility for less-experienced endoscopists who are unfamiliar with third-space techniques. In our study, mean hospitalization time was 1.3 days, aligning with recent findings.

We achieved an exceptionally high clinical success rate of 100%, exceeding those reported in the literature. While this could be partially attributed to the smaller sample size or to the additive experience in third-space endoscopic procedures, our deeper esophageal myotomy (at least 2 cm) may also have contributed. This contrasts with some centers that limit the esophageal myotomy depth to 1 cm, potentially explaining our greater success rate. Moreover, during follow-up, no remaining septum or mucosal flap was observed.

No cases of mucosotomy or perforation occurred, highlighting the safety of these techniques. However, 1 patient developed aspiration pneumonia after accidental closure of the esophagus with clips. Clip removal and re-closure resolved the issue, and led to adjustments in our approach for subsequent cases.

Importantly, several limitations must be considered: the study's retrospective design, the small sample size, the lack of randomization between groups, and experienced endoscopist involvement with an era effect. Improved procedural speed across groups could partially be attributed to increased experience. Nonetheless, the total duration of TF Z-POEM was 15-30 min shorter than that reported by other academic centers.

This study provides initial evidence that TF Z-POEM, by incorporating direct mucosotomy over the septum, deep esophageal myotomy, and a tunnel-free approach, simplifies and accelerates the Z-POEM procedure without compromising efficacy. Further studies are needed to investigate its long-term success and generalizability across endoscopists with diverse experience levels. These investigations will be key to assessing the technique's true potential to redefine the practice of Z-POEM.

Summary Box

What is already known:

- Zenker's peroral endoscopic myotomy (Z-POEM) is an efficient technique for the treatment of Zenker's diverticulum
- The usual duration of Z-POEM in referral centers ranges between 45 and 60 min
- The usual length of esophageal myotomy is limited to 1 cm

What the new findings are:

- This is the first case series of tunnel free Z-POEM combined with direct mucosotomy over the septum and deep myotomy (2 cm)
- This new modification was faster than conventional Z-POEM and equally efficient
- The aforementioned modification simplifies the procedure of Z-POEM and makes it more accessible to less experienced endoscopists

References

1. Li QL, Chen WF, Zhang XC, et al. Submucosal tunneling endoscopic septum division: a novel technique for treating Zenker's diverticulum. *Gastroenterology* 2016;**151**:1071-1074.
2. Brewer Gutierrez OI, Ichkhanian Y, Spadaccini M, Vosoughi K, Repici A, Khashab MA. Zenker's diverticulum per-oral endoscopic myotomy techniques: changing paradigms. *Gastroenterology* 2019;**156**:2134-2135.
3. Mavrogenis G, Tsevgas I, Zachariadis D, Bazerbachi F. Mucosotomy at the top of the septum facilitates tunneling and clipping during peroral endoscopic myotomy for Zenker's diverticulum (Z-POEM). *Ann Gastroenterol* 2020;**33**:101.
4. Repici A, Spadaccini M, Belletrutti PJ, et al. Peroral endoscopic septotomy for short-septum Zenker's diverticulum. *Endoscopy* 2020;**52**:563-568.
5. Mavrogenis G, Maurommatis E, Koumentakis C, Tsevgas I, Zachariadis D, Bazerbachi F. Single-tunnel Zenker's diverticulum peroral endoscopic myotomy. *Endoscopy* 2023;**55**:E604-E605.
6. Mavrogenis G, Bazerbachi F. Peroral endoscopic myotomy for Zenker's diverticulum without tunneling. *Endoscopy* 2023;**55**:E946-E948.
7. Estevinho MM, Pinho R, Rodrigues J, Correia J, Freitas T. Tunneling-free peroral endoscopic septotomy for Zenker diverticulum. *VideoGIE* 2023;**8**:295-297.
8. Dakkak M, Bennett JR. A new dysphagia score with objective validation. *J Clin Gastroenterol* 1992;**14**:99-100.
9. Yang J, Novak S, Ujiki M, et al. An international study on the use of peroral endoscopic myotomy in the management of Zenker's diverticulum. *Gastrointest Endosc* 2020;**91**:163-168.
10. Elkholy S, El-Sherbiny M, Delano-Alonso R, et al. Peroral endoscopic myotomy as treatment for Zenker's diverticulum (Z-POEM): a multi-center international study. *Esophagus* 2021;**18**:693-699.
11. Cotton PB, Eisen GM, Aabakken L, et al. A lexicon for endoscopic adverse events: report of an ASGE workshop. *Gastrointest Endosc* 2010;**71**:446-454.
12. Steinway S, Zhang L, Amundson J, et al. Long-term outcomes of Zenker's peroral endoscopic myotomy (Z-POEM) for treatment of Zenker's diverticulum. *Endosc Int Open* 2023;**11**:E607-E612.