

Benefit of radiofrequency ablation after widespread endoscopic resection of neoplastic Barrett's esophagus in daily practice

Sébastien Godat^{a*}, Mariola Marx^{a*}, Fabrice Caillol^b, Maxime Robert^a, Aurélie Autret^c, Erwan Bories^b, Christian Pesenti^b, Jean Philippe Ratone^b, Alain Schoepfer^a, Flora Poizat^d, Marc Giovannini^b

CHUV, Lausanne, Switzerland; Paoli-Calmettes Institute, Marseille, France

Abstract

Background High-grade dysplasia (HGD) and intramucosal carcinoma (IMC) in Barrett's esophagus (BE) are now well-established indications for endoscopic resection (ER). Radiofrequency ablation (RFA) can be combined with ER in case of flat or long-segment BE ablation. We report here our experience of complementary RFA after widespread ER of neoplastic BE in daily practice.

Method We retrospectively reviewed data of 89 patients, treated between 2006 and 2013 by ER alone (group 1) or by ER combined with RFA (group 2).

Results Fifty-five patients in group 1 (7F/48M, mean age 68 years) underwent widespread ER with eradication of residual non-dysplastic BE. Complete eradication of HGD/IMC and intestinal metaplasia (IM) was achieved in 32/32 (100%) and 48/55 (87.3%) patients, respectively. Thirty-four patients in group 2 (3F/31M, mean age 67 years) had a multimodal treatment strategy, with widespread ER followed by RFA. Mean Prague classification of BE in this group was significantly longer (C4.4M6.6 vs. C2.7M4.5, $P < 0.001$). Complete eradication of HGD/IMC and non-dysplastic BE was confirmed in 26/27 (96.3%) and 20/34 (58.8%) patients, respectively. There was no significant difference between groups concerning adverse events (16.4% vs. 23.5%, $P = 0.58$) or recurrence rate of HGD/IMC (9.1% vs. 14.7%, $P = 0.42$). The mismatch rate between preoperative and final histological diagnosis was high in both groups, at 45.5% and 26.5%.

Conclusions A combination of ER and RFA can treat significantly longer neoplastic BE than ER alone, with the same efficiency and safety. Widespread ER, in contrast, is the only method of obtaining a reliable histological diagnosis.

Keywords Barrett's esophagus, high-grade dysplasia, esophageal cancer, endoscopic resection, radiofrequency ablation

Ann Gastroenterol 2022; 35 (1): 34-41

Division of ^aGastroenterology and Hepatology, CHUV, Lausanne, Switzerland (Sébastien Godat, Mariola Marx, Maxime Robert, Alain Schoepfer); ^bGastroenterology, Paoli-Calmettes Institute, Marseille, France (Fabrice Caillol, Erwan Bories, Jean Philippe Ratone, Marc Giovannini); ^cBiostatistics, Paoli-Calmettes Institute, Marseille, France (Aurélie Autret); ^dDivision of Pathology, Paoli-Calmettes Institute, Marseille, France (Flora Poizat)

Conflict of Interest: None

*Equal contributions

Correspondence to: Dr Sébastien Godat, MD, Division of Gastroenterology and Hepatology, Centre Hospitalier Universitaire Vaudois (CHUV) University of Lausanne, Rue du Bugnon 44, CH-1011 Lausanne, Switzerland, e-mail: Sebastien.Godat@chuv.ch

Received 9 October 2020; accepted 2 March 2021; published online 6 December 2021

DOI: <https://doi.org/10.20524/aog.2021.0685>

Introduction

Barrett's esophagus (BE) is the replacement of squamous mucosa by specialized intestinal metaplasia and represents a risk factor for the development of esophageal cancer, according to the sequence: metaplasia – low-grade dysplasia (LGD) – high-grade dysplasia (HGD) – esophageal adenocarcinoma (EAC) [1]. Nowadays, the perioperative morbidity, as well as the mortality risk associated with surgical esophageal resection, still remains non-negligible, even for procedures performed by experienced teams [2-5]. In contrast, the risk of lymph node metastasis in adenocarcinoma confined to the mucosal or superficial submucosal layer (sm1) with low-risk features is $< 1.5\%$ [6-10]. Based on these considerations, HGD and superficial EAC in BE are now well-established indications for endotherapy (ET) [1,11], allowing preservation

of the esophageal anatomy with an excellent safety profile and a curative efficiency up to 98% [12,13]. The associated morbidity is lower than that of surgery, with a maximum morbidity rate of 19% and a mortality rate of 0%, while most studies on the subject found even lower morbidity rates [14,15].

Long-term data have confirmed that complete eradication of non-dysplastic BE after treatment of neoplastic lesions is crucial to reduce the risk of tumor recurrence and metachronous lesions [15,16]. However, for a long time there was disagreement as to whether endoscopic resection (ER) or thermal ablation was the preferred eradication strategy for remaining BE, balancing the advantage of histological reliability against potential adverse events, such as bleeding, perforation or post-interventional stenosis [17].

The currently recommended management is to combine endoscopic mucosal resection (EMR) or endoscopic submucosal dissection (ESD) of all visible or irregular lesions, complemented by radiofrequency ablation (RFA) of all flat remnant Barrett's tissue [18]. This combination therapy provides the advantage of a histopathologically confirmed diagnosis and has shown equivalent or better results compared to RFA alone for neoplastic BE, with a low recurrence rate <10% for neoplastic and minor non-dysplastic BE [18-21].

Until 2010, the policy in our endoscopy unit was to perform a concomitant complete macroscopic resection of metaplastic BE in cases of ET for neoplastic lesions. From 2010, RFA was used as adjuvant therapy in the management of Barrett's with HGD/intramucosal carcinoma (IMC), to eradicate residual intestinal metaplasia (IM) after widespread ER [14,22,23]. The principal objective of our study was to analyze the benefit and safety of complementary RFA in current practice compared to widespread ER alone.

Patients and methods

We carried out a retrospective observational study in a single tertiary referral endoscopy center, monitored and approved by the Institutional Review Board. From computerized and retrospectively collected data of our endoscopy and hospital database (4D program®), we retrieved all patients who underwent ET for neoplastic or dysplastic BE between 2006 and 2013. In the absence of recent data, we obtained supplementary parameters by contacting the patients' general practitioners or referring gastroenterologists. The various clinical, endoscopic, histopathological and technical characteristics were manually collected in a computer database and finally analyzed by an affiliated biostatistician. We recorded patients' characteristics, initial macroscopic Barrett's length using the Prague classification, detailed description of ET sessions, histological diagnosis based on preoperative biopsies and on the specimen after resection, occurrence and treatment of adverse events, delay between initial endoscopic treatment and relapse, the rate of cancerous progression, as well as the rate of salvage therapy, such as chemoradiotherapy or surgery.

Inclusion criteria were defined as the presence of HGD or EAC on pre-resection biopsies or on histological specimen after

ER. For early esophageal carcinoma we required tumor-free resection margins with a maximum depth infiltration of m3 according to the Japanese Society of Esophageal Disease [24]. Lesions infiltrating the submucosa (T1b) were excluded in accordance with our institution's policy.

ER, for both visible lesions and the majority of surrounding BE tissue, was done by EMR or ESD, depending on the practitioner's choice, given the macroscopic presentation and histopathological evaluation. EMR procedures were accomplished using a snare or the multiband ligation Duette® device (Cook Medical) after submucosal injection of saline solution colored by indigo carmine. To perform ESD we used the Dual Knife® (Olympus) after outline marking and submucosal injection of saline solution colored by indigo carmine. Both EMR and ESD were preferentially performed semi-circumferentially, except for circumferential resection in some cases of short BE. If diminutive residual BE islands were found in the combination treatment group, we erased the residual BE area using adjuvant RFA (Covidien®). If symptomatic esophageal stricture occurred, we performed endoscopic balloon dilation (Hercules®) in as many sessions as were necessary to resolve dysphagia and to permit new ER. All patients were on a standard dose of a proton pump inhibitor b.i.d. during and after completion of ET. ET sessions were carried out every 4-12 weeks.

Endoscopic monitoring was performed every 6 months after treatment, with targeted biopsies taken if there were suspicious lesions. Systematic biopsies were performed on the Z-line if no suspicious lesion was visualized. Macroscopic eradication of metaplastic BE was considered as the end of treatment, while histological confirmation was not mandatory. In contrast, eradication of HGD/EAC had to be systematically confirmed by histopathological analysis. Once ET was completed, patients were recommended to continue biannual endoscopic and histological follow up.

We analyzed the outcomes of 2 different subgroups: patients in group 1 were treated by widespread ER alone, including the visible lesion and the surrounding BE, whereas patients in group 2 had a multimodal treatment strategy with widespread ER followed by RFA. Treatment success was defined as the absence of HGD/IMC during endoscopic and histological control after at least 6 months of follow up. ET has been considered as failure if eradication of the neoplastic part of BE required more than 3 sessions, based on the histopathological analysis of the resected mucosa. Additional treatment sessions for complete eradication of non-dysplastic BE have been accepted. We defined relapse as the occurrence of HGD/IMC in any localization within the BE mucosa after initial treatment success, which means after one negative endoscopic control and not less than 6 months of follow up.

Results

Between 2006 and 2013, 92 patients underwent ET for neoplastic BE. Since 3 patients with an infiltration depth of sm1/sm2 (T1b) were excluded, our results are based on 89 patients. Until 2010, a total of 31 patients underwent ER; 13

of them underwent additional treatment by RFA when it was available after 2010. In the period from 2010-2013, 37 patients were treated by ER alone, while in 21 patients we performed a combination of ER followed by RFA (Fig. 1). Mean follow-up time for all patients was 23.6 months (range 6-84, 95% confidence interval [CI] 19.6-28.1).

Patients' baseline characteristics

Fifty-five patients with a mean age of 68 years, 48 men and 7 women, were treated by ER alone (Table 1). Their mean BE length was C2.7 cm (range 0-14 cm, 95%CI 1.7-3.7), M4.5 cm (range 1-17 cm, 95%CI 3.7-5.2). At initial macroscopic evaluation, visible lesions presented a mean size of 16.5 mm (range 8-30 mm) and were described as nodular in 17 cases (30.9%, Paris 0-Is/0-IIa), as flat in 36 (65.4%, Paris 0-IIb) and depressed in 2 cases (3.6%, Paris 0-IIc). Histological preoperative analysis revealed HGD in 53 (96%) samples (Table 2). In contrast, resection specimens confirmed HGD in 13 (23.6%), but LGD in 16 (29.1%) and intestinal metaplasia in 7 (12.7%) cases. IMC was found in 4 (7.3%) patients classified as pT1m2N0M0, and in 15 (27.3%) patients classified as pT1m3N0M0. Two patients with LGD on preoperative samples, but endoscopically suspect lesions, showed HGD on a surgical specimen. The total mismatch rate between presumptive and final histological diagnosis was 45.5% (Table 2).

Treatment combining ER and RFA was performed in 34 patients, 31 men and 3 women, with a mean age of 67 years and a mean BE Prague classification of C4.4 cm (range 0-13 cm, 95%CI 3.3-5.8), M6.6 cm (range 2-13 cm, 95%CI 5.7-7.4). Visible lesions were endoscopically characterized as nodular

in 8 patients (23.5%, Paris 0-Is/0-IIa), as flat in 23 (67.6%, Paris 0-IIb) and as depressed in 3 patients (8.8%, Paris 0-IIc). Their mean size was 13.4 mm (range 10-25 mm). Preoperative histological analysis was positive for HGD in 32 (94.1%) patients and for LGD in 2 (5.9%) patients. Final histological diagnosis after resection revealed HGD in 13 (38.2%) and LGD in 5 (14.7%) patients, with metaplasia and normal stratified squamous epithelium in 1 (2.9%) case. IMC was found in 14 patients, 5 (14.7%) cases classified as pT1m2N0M0 and 9 (26.5%) cases as pT1m3N0M0. The mismatch rate between preoperative and definitive histological diagnosis was 26.5%.

Treatment

In patients treated exclusively by ER (group 1), EMR procedures were performed in a total of 53 (96.4%) patients, using a snare technique in 8 (14.5%) patients, multiband ligation with the Duette® device in 30 (54.5%) patients and a dual-channel scope in 15 (27.3%) patients (Table 3). Two (3.6%) patients underwent ESD.

EMR in group 2 (ER+RFA) was carried out in 31 (91.2%) patients. Multiband ligation with the Duette® device was used in 18 (52.9%) subjects, a snare technique in 7 (20.6%) and resection by the dual-channel scope in 6 (17.6%). ESD was performed in 3 (8.8%) patients. All patients in this group underwent combination therapy. Focal residual BE areas were treated in all 34 patients by RFA with the Halo 90° device in a mean number of 1.6 (range 1-4) sessions. Six of them had additional circumferential RFA using the Halo 360° device in only one session per patient. There was no significant difference in mean treatment duration, requiring 1.8 treatment sessions (range 1-4) over 4.8 (range 2-12) months in group 1 and 2 treatment sessions (range 1-7) over 5.1 (range 2-13) months in group 2.

Adverse events and safety outcomes

Complications occurred in 8 of the 34 (23.5%) patients who received combination therapy, compared with 9 of the 55 (16.4%) patients who had ER alone (Table 4). There were no deaths related to ET in either group. Stricture development was observed in 8 patients who had ER alone (14.5%). Three of them developed stenosis after one circumferential mucosal resection, 1 patient after a 75% resection, 2 patients after the second hemi-circumferential resection, while in 2 patients the resected surface was not exactly quantified. In 6 patients treated by combination therapy, esophageal stenosis occurred after widespread ER and not after RFA sessions (17.6%): in 2 patients after the first hemi-circumferential resection, in 2 patients after the second hemi-circumferential resection and in 2 patients after large resection (area not quantified). Of the 6 patients treated using the Halo 360° device, none showed post-interventional stenosis. Subsequent esophageal stenosis required endoscopic dilatation in a mean number of 2.1 and 2.3 sessions for groups 1 and 2, respectively. There were no stricture recurrences on successive endoscopies.

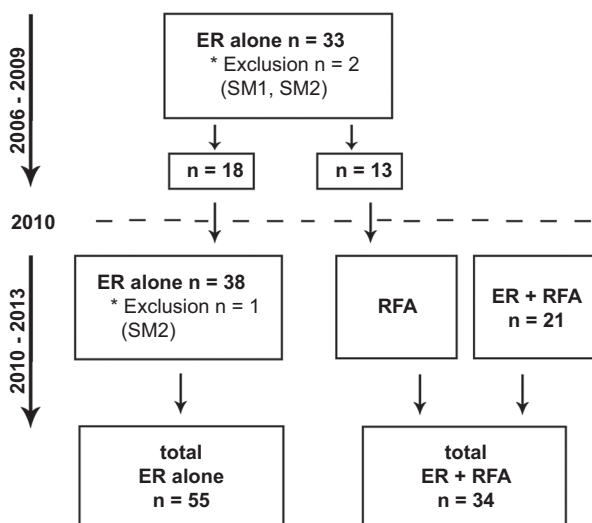


Figure 1 Flowchart showing endoscopic treatment of included patients: Until 2010 patients have exclusively been treated by endoscopic resection (ER) for neoplastic Barrett's esophagus (BE) and eradication of remnant non-dysplastic BE. Complementary treatment for non-dysplastic BE by radiofrequency ablation (RFA) was introduced later and mainly used in long BE >5 cm after resection of neoplastic BE

Table 1 Baseline characteristics of included patients

Characteristics	Group 1: ER	Group 2: ER+RFA
Number of patients, n	55	34
Sex, n [%]	♂48 ♀7	♂31 ♀3
Age, mean [range] in years	68 [48-86]	67 [40-88]
ASA score, mean	2.1	2.1
Initial Prague classification, mean in cm [range; CI]	C2.7 [0-14; 1.7-3.7] M4.5 [1-17; 3.7-5.2]	C4.4 [0-13; 3.3-5.8] M6.6 [2-13; 5.7-7.4]
Initial macroscopic presentation, n [%]		
Paris classification		
0-Is/0-IIa	17 [30.9]	8 [23.5]
0-IIb	36 [65.4]	23 [67.6]
0-IIc	2 [3.6]	3 [8.8]
Initial size of cancerous nodule, mean, mm [range]	16.5 [8-30]	13.4 [10-25]
≤20 mm, n [%]	14 [25.4]	9 [26.4]
>20 mm, n [%]	4 [7.3]	2 [5.9]

ER, endoscopic resection; RFA, radiofrequency ablation; ASA, American Society of Anesthesiologists; ♂, male; ♀, female, Prague classification, C circumferential and M maximum length of Barrett's esophagus; CI, confidence interval

Table 2 Preoperative and final histological diagnosis

Groups	Preoperative diagnosis	n [%]	Final histological diagnosis on surgical specimen	n [%]
Group 1 (ER alone)	LGD	2 [3.6]	HGD	2 [3.6]
	HGD	53 [96.4]	Normal squamous epithelium	0 [0]
			Metaplasia	7 [12.7]
			LGD	16 [29.1]
			HGD/pTisN0M0	11 [20]
			Intramucosal carcinoma	
			pT1m2N0M0	4 [7.3]
pT1m3N0M0	15 [27.3]			
Group 2 (ER+RFA)	LGD	2 [5.9]	HGD	2 [5.9]
	HGD	32 [94.1]	Normal squamous epithelium	1 [2.9]
			Metaplasia	1 [2.9]
			LGD	5 [14.7]
			HGD/pTisN0M0	11 [32.4]
			Intramucosal carcinoma	
			pT1m2N0M0	5 [14.7]
pT1m3N0M0	9 [26.5]			

ER, endoscopic resection; RFA, radiofrequency ablation; LGD, low-grade dysplasia; HGD, high-grade dysplasia

Perforation occurred in one patient treated by EMR alone (1.8%), whereas there was no perforation in patients with combination therapy. The mucosal defect was successfully closed by temporary placement of an esophageal stent. Of the patients who underwent EMR followed by RFA, 2 (5.9%) suffered perioperative bleeding, managed by endoscopic hemostasis. In summary, complication rates did not differ statistically between the 2 treatment groups ($P=0.58$) and all complications could be treated conservatively or endoscopically.

Efficacy outcomes

Complete eradication for intestinal metaplasia was achieved in 20 of 34 patients who had RFA after ER (58.8%),

compared to 48 of the 55 patients treated by ER alone (87.3%). In contrast, the complete eradication rate for neoplastic BE was equivalent for both groups, as set out in Table 5. Thus, treatment success by ER alone (group 1) was confirmed in all 32 patients. In patients getting combination therapy by ER and RFA (group 2) treatment failure was observed in only one patient, while complete eradication was successful in 26 of 27 (96.3%, $P=0.93$) patients.

We observed no significant difference between the 2 groups in the recurrence rate of HGD or neoplasia, with a relapse rate of 9.1% (5/55) in patients treated by ER alone and a relapse rate of 14.7% (5/34) in patients treated by ER and RFA ($P=0.42$) (Table 6). The mean interval between complete eradication and relapse was 16.6 months in group 1 (ER alone) and 18.2 months in group 2 (ER+RFA). We observed the latest relapse after 33 months in group 1 and after 28 months in group 2. Recurrent

Table 3 Endoscopic treatment strategy

Endotherapy	Group 1: ER	Group 2: ER+RFA
Endoscopic resection, n [%]		
EMR		
Snare	8 [14.5]	7 [20.6]
Dual channel	15 [27.3]	6 [17.6]
Multiband ligation EMR, Duette®	30 [54.5]	18 [52.9]
ESD	2 [3.6]	3 [8.8]
Number of ER sessions, mean [range]	1.8 [1-4]	1.97 [1-7]
RFA, n (%)		
Halo 90°	NA	34 [100]
Halo 360°		6 [17.6]
Number of RFA sessions, mean [range]	NA	1.62 [1-4]
Halo 360°		1 session per patient
Duration of treatment, months, mean [range]	4.8 [2-12]	5.1 [2-13]

ER, endoscopic resection; RFA, radiofrequency ablation; EMR, endoscopic mucosal resection; ESD, endoscopic submucosal dissection

Table 4 Adverse events

Adverse events	Group 1: ER	Group 2: ER+RFA
Perioperative bleeding, n [%]	0	2 [5.9]
Stricture development, n [%]	8 [14.5]	6 [17.6]
Perforation, n [%]	1 [1.8]	0
Death, n [%]	0	0
Number of endoscopic dilation sessions, mean [range]	2.1 [2-3]	2.3 [2-3]
Total rate of adverse events, [%]	16.4	23.5

ER, endoscopic resection; RFA, radiofrequency ablation

Table 5 Treatment success after ER alone versus ER+RFA

Complete eradication	Group 1: ER	Group 2: ER+RFA
Metaplasia, n [%]	48/55 [87.3]	20/34 [58.8]
LGD, n [%]	15/16 [93.8]	5/5 [100]
HGD/pTisN0M0 or intramucosal carcinoma, n [%]	13/13 [100]	12/13 [92.3]
IMC, n [%]		
pT1m2N0M0	4/4 [100]	5/5 [100]
pT1m3N0M0	15/15 [100]	9/9 [100]
Total eradication rate for HGD or IMC, %	100	96.3

ER, endoscopic resection; RFA, radiofrequency ablation; LGD, low-grade dysplasia; HGD, high-grade dysplasia; is, in situ; IMC, intramucosal carcinoma

disease was first treated endoscopically. Complementary surgical management was needed in 5 (9.1%) patients treated by ER alone and in 1 (2.9%) patient treated by ER and RFA. Two (3.6%) patients in group 1 and 1 (2.9%) patient in group 2 had complementary chemoradiotherapy. There was no death related to the disease. One patient presented metastatic progression, but died finally in an accident 77 months after the initial treatment.

Table 6 Long-term outcome after endotherapy

Relapse and follow up	Group 1: ER	Group 2: ER+RFA
Relapse rate, n [%]	5/55 [9.1]	5/34 [14.7]
Delay for relapse, mean [range] in months	16.6 [6-33]	18.2 [7-28]
Metastasis progression, n [%]	1 [1.8]	0
Deaths related to the disease, n [%]	0	0
Deaths unrelated to the disease, n [%]		
Accidental death	1 [1.8]	0
Concomitant pancreatic cancer	0	1 [2.9]
Sepsis post esophagectomy for relapse	1 [1.8]	0
Complementary surgical management for relapse, n (%)	5 [9.1]	1 [2.9]
Complementary chemoradiotherapy for relapse, n (%)	2 [3.6]	1 [2.9]

ER, endoscopic resection; RFA, radiofrequency ablation

Discussion

ET is the standard of care for HGD and early neoplastic lesions in BE, and is associated with lower morbidity and mortality compared to surgery [3,25]. Recent studies provided good evidence for excellent long-term outcomes [12,26]. ER preserves the esophageal anatomy, while the histological analysis of the resected specimen allows the need for further surgical therapy to be defined, depending on tumor differentiation, infiltration depth and lymphovascular invasion.

Current guidelines recommend ER of every visible abnormality containing any degree of dysplasia or neoplasia, followed by complete eradication of all remaining Barrett's epithelium, preferably by RFA [27]. Widespread ER remains common practice in some endoscopy units, as is the case in our department, whereas adjuvant RFA is primarily reserved for eradication of long segment BE after ER of neoplastic lesions [12,22,23,28].

We report here on our experience in the management of neoplastic BE, based on a retrospective analysis of patients treated by ER alone vs. a combination of ER followed by RFA. RFA was introduced in our endoscopy unit in 2010. At the beginning, the French health insurance did not completely cover costs and RFA had to be employed with restrictions due to financial issues. Thus, our results are based on a heterogeneous treatment management, but reflect outcomes in current daily practice.

Patients' baseline characteristics were found to be similar in both groups, except for the circumferential and maximum extent of Barrett's mucosa, significantly longer in patients undergoing combination therapy than in patients treated by ER alone (mean Prague classification C4.4M6.6 vs C2.7M4.5, $P < 0.001$). This trend towards longer BE observed in patients treated by ER+RFA (mainly after 2010), could be associated with an increase in the prevalence of gastroesophageal reflux disease during the last decades and is concordant with the growing incidence of EAC [29,30]. Furthermore, this difference might be in part explained by our department's policy, using adjuvant RFA for treatment of remnant BE > 5 cm to reduce the risk of esophageal stricture formation, as RFA shows lower esophageal stricture rates compared to ER [13]. In contrast, large mucosal resection and resection of multiple lesions on the initial procedure are known risk factors for esophageal stricture formation [31]. Esophageal stenosis is a well described and challenging complication of ET, which might impede ongoing treatment by contraindicating complementary resection/ablation. Furthermore, repetitive therapeutic dilations bear a non-negligible risk of perforation. There are similar results in the USA RFA Registry, analyzing data from 1263 patients with HGD or IMC, treated by EMR for nodular lesions before RFA in 406 (32%) and by RFA only in 857 (68%) patients in the case of non-nodular BE. While there were no differences concerning the efficacy of eradication or complications, the investigators found that the BE length of patients treated by EMR before RFA was shorter than that of patients treated with RFA only (4.6 vs. 5.4 cm, $P < 0.001$) [32].

Despite the discrepancy in BE length, there was no significant difference between the groups concerning the complete eradication rate of HGD or IMC (100% vs. 96.3%, $P = 0.93$), suggesting that combination treatment allows larger Barrett's areas to be treated with no decrease in efficacy. In addition, combination treatment did not increase the rate of procedure-related complications. The occurrence of esophageal strictures has mainly been observed after ER, even in patients treated by combination therapy. However, dilation of the stenosis was always successful and never hampered later treatment by ER or RFA.

In contrast, treatment success for eradication of intestinal metaplasia was significantly higher in patients treated by widespread resection alone, compared to the multimodal endoscopic treatment group (87.3% vs. 58.8%, $P = 0.002$), probably reflecting a suboptimal implementation of RFA due to cost issues. Indeed, RFA was performed in a mean number of 1.6 sessions (range 1-4), until eradication of endoscopic visible BE. In contrast, prospective studies published during

recent years performed a median of 3-4 sessions, with histological confirmation of non-dysplastic BE eradication [18]. Though we required histologically confirmed eradication of neoplastic BE, eradication of non-dysplastic BE was based on macroscopic evaluation. The decision in favor of macroscopic IM eradication—and thus against performance of RFA without visible lesions—was influenced by the risk/benefit ratio, considering the slightly elevated risk of relapse acceptable to minimize the risk of repeated interventions and general anesthesia.

The above-mentioned difference in IM eradication rate may also explain in part the sustainability of the treatment response: thus, we found a higher, though not statistically significant, relapse rate of HGD/EAC in patients treated by multimodal therapy compared to ER alone (14.7% vs. 9.1%, $P = 0.42$). Because of a lack of awareness at the beginning of this study, we did not report the localization of relapse, and we assume that in some cases "relapse" may represent a metachronous lesion rather than a real local recurrence. The first good evidence suggesting a benefit from complete eradication of IM was published by Pech *et al* in 2008: the investigators detected significantly less metachronous neoplasia in patients receiving ablation therapy compared to patients without complementary treatment (16.5 vs. 29.9%) [15]. These data correlate with our previous published study, showing a relapse rate of 3.4% (1/29 patients) in case of complete eradication of metaplastic BE, but 31% (9/29) in case of incomplete eradication [16]. However, the present study included patients from 2006-2013 and the importance of complete eradication of IM only became evident during the later years and was not so obvious at the beginning of our study. Thus, our results underline once again the importance of complete eradication of remaining BE after treatment of HGD/EAC to decrease the risk of neoplasia relapse.

The management of relapse in patients treated by widespread resection alone required more complementary surgical and chemoradiotherapeutic treatment sessions than in the ER+RFA treatment group. Complementary surgical management was needed in all 5 relapsed patients (9.1%) treated by ER alone. Only 1 patient presenting relapse in the ER+RFA group underwent surgery. Two patients in group 1 (3.6%) and 1 patient in group 2 (2.9%) had complementary chemoradiotherapy. Though recurrent lesions were first treated by endoscopic treatment, most of the reported cases occurred before the implementation of ESD in our endoscopy unit: thus, management of complicated relapse was technically difficult, and this may in part explain the substantial use of secondary surgery [33].

The key point of our present study is a significantly higher mismatch between the preoperative and final histological diagnosis in patients treated by ER alone than in patients treated by combination therapy (45.4 vs. 26.5%), suggesting that the greater the therapeutic resection, the more likely we are to get a reliable histological diagnosis. Preoperative biopsies of suspect lesions in BE are known to have poor reliability, and 3 patients with initial HGD were diagnosed with submucosal infiltration (T1b) after widespread resection. They were referred for further surgical management. Thus, complete

resection continues to be the preferred procedure to obtain an accurate histological classification [28,34-36].

Histological staging by ER is crucial to determine a patient's optimal treatment strategy. According to the USA RFA Registry, the relapse rate was shown to be lower in case of ER of visible lesions preceding RFA, despite a comparable complete eradication rate of advanced dysplasia or IMC in both groups. Thus, 1.5% (5/331) of patients who had EMR before RFA progressed to invasive neoplasia, whereas 3.6% (24/663) of patients treated by RFA alone developed invasive adenocarcinoma ($P=0.07$). Among the latter 24 patients, 23 progressed from HGD [32]. These data suggest that, when RFA is used for treatment of non-nodular HGD, more advanced lesions might be missed and might progress to invasive adenocarcinoma.

In a retrospective study of 78 patients in 4 tertiary medical centers in the US, EMR prior to RFA as the primary treatment for biopsy-proven IMC significantly reduced the risk of treatment failure, observed in 4/6 patients treated by RFA alone vs. 13/72 patients treated by ER+RFA (hazard ratio 0.15, 95%CI 0.05-0.48; $P=0.001$) [37]. Similarly, in the UK patient registry, the rate of ER of visible suspicious lesions prior to RFA increased between 2008 and 2013 from 48% to 68% ($P=0.013$). In the same time, the relapse rate decreased from 13% to 2%, suggesting that ER improves the efficacy of endoscopic treatment of BE [17].

To conclude, the association of RFA with widespread ER does not increase the complication rate, but allows ET of significantly longer neoplastic BE with similar treatment success. However, the use of RFA needs careful consideration, given that it does not enable accurate histological staging. ER, in contrast, is the only method to obtain a reliable histological diagnosis.

Summary Box

What is already known:

- High-grade dysplasia (HGD) and intramucosal carcinoma (IMC) in Barrett's esophagus (BE) are well-established indications for endoscopic treatment
- Radiofrequency ablation (RFA) can be associated with endoscopic resection (ER) in case of flat or long-segment BE ablation

What the new findings are:

- The combination of ER and RFA can treat significantly longer BE with HGD/IMC than ER alone, with the same efficacy
- A multimodal treatment strategy (ER+RFA) does not increase the complication rate of endotherapy
- ER is mandatory to ensure a correct histological diagnosis of HGD and IMC

References

1. Shaheen NJ, Falk GW, Iyer PG, Gerson LB; American College of Gastroenterology. ACG Clinical Guideline: Diagnosis and management of Barrett's esophagus. *Am J Gastroenterol* 2016;**111**:30-50.
2. Awad ZT, Abbas S, Puri R, Dalton B, Chesire DJ. Minimally invasive Ivor Lewis esophagectomy (MILE): technique and outcomes of 100 consecutive cases. *Surg Endosc* 2020;**34**:3243-3255.
3. Bennett C, Vakil N, Bergman J, et al. Consensus statements for management of Barrett's dysplasia and early-stage esophageal adenocarcinoma, based on a Delphi process. *Gastroenterology* 2012;**143**:336-346.
4. Song EY, Frakes JM, Extermann M, et al. Clinical factors and outcomes of octogenarians receiving curative surgery for esophageal cancer. *J Surg Res* 2020;**251**:100-106.
5. Yibulayin W, Abulizi S, Lv H, Sun W. Minimally invasive oesophagectomy versus open esophagectomy for resectable esophageal cancer: a meta-analysis. *World J Surg Oncol* 2016;**14**:304.
6. Alvarez Herrero L, Pouw RE, van Vilsteren FG, et al. Risk of lymph node metastasis associated with deeper invasion by early adenocarcinoma of the esophagus and cardia: study based on endoscopic resection specimens. *Endoscopy* 2010;**42**:1030-1036.
7. Dunbar KB, Spechler SJ. The risk of lymph-node metastases in patients with high-grade dysplasia or intramucosal carcinoma in Barrett's esophagus: a systematic review. *Am J Gastroenterol* 2012;**107**:850-862.
8. Hirasawa K, Kokawa A, Oka H, et al. Superficial adenocarcinoma of the esophagogastric junction: long-term results of endoscopic submucosal dissection. *Gastrointest Endosc* 2010;**72**:960-966.
9. Manner H, May A, Pech O, et al. Early Barrett's carcinoma with "low-risk" submucosal invasion: long-term results of endoscopic resection with a curative intent. *Am J Gastroenterol* 2008;**103**:2589-2597.
10. Pimentel-Nunes P, Dinis-Ribeiro M, Ponchon T, et al. Endoscopic submucosal dissection: European Society of Gastrointestinal Endoscopy (ESGE) Guideline. *Endoscopy* 2015;**47**:829-854.
11. Wu J, Pan YM, Wang TT, Gao DJ, Hu B. Endotherapy versus surgery for early neoplasia in Barrett's esophagus: a meta-analysis. *Gastrointest Endosc* 2014;**79**:233-241.
12. Pouw RE, Seewald S, Gondrie JJ, et al. Stepwise radical endoscopic resection for eradication of Barrett's oesophagus with early neoplasia in a cohort of 169 patients. *Gut* 2010;**59**:1169-1177.
13. van Vilsteren FG, Pouw RE, Seewald S, et al. Stepwise radical endoscopic resection versus radiofrequency ablation for Barrett's oesophagus with high-grade dysplasia or early cancer: a multicentre randomised trial. *Gut* 2011;**60**:765-773.
14. Caillol F, Bories E, Pesenti C, et al. Radiofrequency ablation associated to mucosal resection in the oesophagus: experience in a single centre. *Clin Res Hepatol Gastroenterol* 2012;**36**:371-377.
15. Pech O, Behrens A, May A, et al. Long-term results and risk factor analysis for recurrence after curative endoscopic therapy in 349 patients with high-grade intraepithelial neoplasia and mucosal adenocarcinoma in Barrett's oesophagus. *Gut* 2008;**57**:1200-1206.
16. Caillol F, Godat S, Autret A, et al. Neoplastic Barrett's oesophagus and long-term follow-up after endoscopic therapy: complete histological eradication of Barrett associated with high-grade dysplasia significantly decreases neoplasia relapse. *Surg Endosc* 2016;**30**:5410-5418.
17. Haidry RJ, Butt MA, Dunn JM, et al; UK RFA Registry. Improvement over time in outcomes for patients undergoing endoscopic therapy for Barrett's oesophagus-related neoplasia: 6-year experience from the first 500 patients treated in the UK patient registry. *Gut* 2015;**64**:1192-1199.
18. Phoa KN, Pouw RE, Bisschops R, et al. Multimodality endoscopic

- eradication for neoplastic Barrett oesophagus: results of an European multicentre study (EURO-II). *Gut* 2016;**65**:555-562.
19. Anders M, Bähr C, El-Masry MA, et al. Long-term recurrence of neoplasia and Barrett's epithelium after complete endoscopic resection. *Gut* 2014;**63**:1535-1543.
 20. de Matos MV, da Ponte-Neto AM, de Moura DTH, et al. Treatment of high-grade dysplasia and intramucosal carcinoma using radiofrequency ablation or endoscopic mucosal resection + radiofrequency ablation: Meta-analysis and systematic review. *World J Gastrointest Endosc* 2019;**11**:239-248.
 21. Phoa KN, van Vilsteren FG, Weusten BL, et al. Radiofrequency ablation vs endoscopic surveillance for patients with Barrett esophagus and low-grade dysplasia: a randomized clinical trial. *JAMA* 2014;**311**:1209-1217.
 22. Giovannini M, Bories E, Pesenti C, et al. Circumferential endoscopic mucosal resection in Barrett's esophagus with high-grade intraepithelial neoplasia or mucosal cancer. Preliminary results in 21 patients. *Endoscopy* 2004;**36**:782-787.
 23. Lopes CV, Hela M, Pesenti C, et al. Circumferential endoscopic resection of Barrett's esophagus with high-grade dysplasia or early adenocarcinoma. *Surg Endosc* 2007;**21**:820-824.
 24. Kuwano H, Nishimura Y, Oyama T, et al. Guidelines for diagnosis and treatment of carcinoma of the esophagus April 2012 edited by the Japan Esophageal Society. *Esophagus* 2014;**12**:1-30.
 25. Pech O, Bollschweiler E, Manner H, Leers J, Ell C, Hölscher AH. Comparison between endoscopic and surgical resection of mucosal esophageal adenocarcinoma in Barrett's esophagus at two high-volume centers. *Ann Surg* 2011;**254**:67-72.
 26. Pech O, May A, Manner H, et al. Long-term efficacy and safety of endoscopic resection for patients with mucosal adenocarcinoma of the esophagus. *Gastroenterology* 2014;**146**:652-660.
 27. Weusten B, Bisschops R, Coron E, et al. Endoscopic management of Barrett's esophagus: European Society of Gastrointestinal Endoscopy (ESGE) Position Statement. *Endoscopy* 2017;**49**:191-198.
 28. Conio M, Fisher DA, Bianchi S, Ruggeri C, Filiberti R, Siersema PD. One-step circumferential endoscopic mucosal cap resection of Barrett's esophagus with early neoplasia. *Clin Res Hepatol Gastroenterol* 2014;**38**:81-91.
 29. Yamasaki T, Hemond C, Eisa M, Ganocy S, Fass R. The changing epidemiology of gastroesophageal reflux disease: are patients getting younger? *J Neurogastroenterol Motil* 2018;**24**:559-569.
 30. Coleman HG, Xie SH, Lagergren J. The epidemiology of esophageal adenocarcinoma. *Gastroenterology* 2018;**154**:390-405.
 31. Qumseya B, Panossian AM, Rizk C, et al. Predictors of esophageal stricture formation post endoscopic mucosal resection. *Clin Endosc* 2014;**47**:155-161.
 32. Li N, Pasricha S, Bulsiewicz WJ, et al. Effects of preceding endoscopic mucosal resection on the efficacy and safety of radiofrequency ablation for treatment of Barrett's esophagus: results from the United States Radiofrequency Ablation Registry. *Dis Esophagus* 2016;**29**:537-543.
 33. Godat S, Caillol F, Autret A, et al. Endotherapy in case of relapse of neoplastic Barrett's esophagus after successful initial endoscopic resection. *Surg Endosc* 2017;**31**:3703-3710.
 34. Caillol F, Godat S, Poizat F, et al. Probe confocal laser endomicroscopy in the therapeutic endoscopic management of Barrett's dysplasia. *Ann Gastroenterol* 2017;**30**:295-301.
 35. Chennat J, Konda VJ, Ross AS, et al. Complete Barrett's eradication endoscopic mucosal resection: an effective treatment modality for high-grade dysplasia and intramucosal carcinoma--an American single-center experience. *Am J Gastroenterol* 2009;**104**:2684-2692.
 36. Moss A, Bourke MJ, Hourigan LF, et al. Endoscopic resection for Barrett's high-grade dysplasia and early esophageal adenocarcinoma: an essential staging procedure with long-term therapeutic benefit. *Am J Gastroenterol* 2010;**105**:1276-1283.
 37. Agoston AT, Strauss AC, Dulai PS, et al. Predictors of treatment failure after radiofrequency ablation for intramucosal adenocarcinoma in Barrett esophagus: a multi-institutional retrospective cohort study. *Am J Surg Pathol* 2016;**40**:554-562.