

Small bowel capsule endoscopy in refractory celiac disease: A luxury or a necessity?

Stefania Chetcuti Zammit^a, Luca Elli^b, Lucia Scaramella^b, David S. Sanders^a, Gian Eugenio Tontini^b, Reena Sidhu^a

Sheffield Teaching Hospitals, United Kingdom; University of Milan, Italy

Abstract

Background Small bowel capsule endoscopy (SBCE) has an established role in the management of refractory celiac disease (RCD) for the detection of complications. The aim of this study was to define the role of SBCE in the management of patients with RCD.

Method Patients with histologically confirmed RCD who underwent successive SBCEs were recruited retrospectively from 2 tertiary centers.

Results Sixty patients with RCD were included. The percentage extent of the affected small bowel (SB) mucosa improved on repeating a second SBCE in 26 patients (49.1%) (median 27.6% vs. 18.1%, $P=0.007$). Patients with RCD type II had more extensive disease than those with RCD type I on first (41.4% vs. 19.2%, $P=0.004$) and second (29.8% vs. 12.0%, $P=0.016$) SBCE. Patients with RCD type I tended to show a greater improvement in percentage of abnormal SB involved on repeat SBCE compared to those with RCD type II ($P=0.049$). Nine patients (15%) had RCD-related complications. Five patients developed ulcerative jejunoileitis, 3 patients developed enteropathy-associated T-cell lymphoma, and 1 patient developed cutaneous T-cell lymphoma.

Conclusions SBCE can be a useful tool for monitoring the effects of treatment, primarily following its initiation. Patients with RCD type II have more extensive SB disease, equating to a more aggressive disease pattern.

Keywords Celiac disease, refractory celiac disease, small bowel capsule endoscopy, extent of disease

Ann Gastroenterol 2021; 34 (1): 1-9

Introduction

Refractory celiac disease (RCD) is a rare complication of celiac disease (CD). In a recent systemic review, the prevalence of RCD was reported to be 0.31-0.38% in patients with CD [1]. It occurs more commonly in females, older individuals

(>50 years), those diagnosed with CD later on in life, and patients with signs suggestive of malabsorption [2-6]. Patients with RCD have traditionally been managed with steroids and/or immunosuppressants, in addition to maintaining a gluten-free diet (GFD). Duodenal histology is repeated at intervals to ensure no progression of RCD type I to type II occurs and to rule out aberrant intraepithelial lymphocytes [7,8]. The prognosis of RCD type II is poor, with a 50% 5-year survival, owing to the development of malignancy, necessitating careful follow-up [9,10]. However, the follow-up interval in these patients and how it should differ between subtypes of RCD remains unclear [3,7,11-13].

Since its introduction in 2000, small bowel capsule endoscopy (SBCE) has enabled the study of several SB pathologies such as CD. Dedicated SB imaging can be helpful to exclude malignancies such as enteropathy associated T-cell lymphoma (EATL) or adenocarcinoma of the SB [14]. However, sometimes pre-malignant or malignant conditions do not necessarily result in lesions of sufficient size to be picked up on imaging, making SBCE a better alternative for delineating these lesions [15]. In addition, SBCE allows the disease extent in the SB to be estimated [16-18]. The relationship between

^aGastroenterology Department, Sheffield Teaching Hospitals, United Kingdom (Stefania Chetcuti Zammit, David S. Sanders, Reena Sidhu); ^bCentre for Prevention and Diagnosis of Coeliac Disease, Gastroenterology and Endoscopy Unit, Department of Pathophysiology and Transplantation, Fondazione IRCCS Ca' Granda Ospedale Maggiore Policlinico, University of Milan, Italy (Luca Elli, Lucia Scaramella, Gian Eugenio Tontini)

Conflict of Interest: None

Correspondence to: Stefania Chetcuti Zammit, Gastroenterology Department, Royal Hallamshire Hospital, S10 2SB, Sheffield, United Kingdom, e-mail: stf_che@yahoo.com

Received 20 September 2020; accepted 27 October 2020; published online 27 January 2021

DOI: <https://doi.org/10.20524/aog.2021.0586>

the disease extent and the severity of CD remains unclear. However, the literature suggests that healing of the mucosa in CD patients occurs in a distal-to-proximal manner [16,17,19].

The main aim of this study was to assess the role of SBCE at diagnosis and its impact on subsequent management and course of disease. Secondary aims were to stratify findings on SBCE according to RCD subtype and treatment administered.

Patients and methods

Study design and patients

Patients with RCD who underwent successive SBCEs were recruited retrospectively from 2 tertiary centers for the management of CD and national centers for the management of RCD (Sheffield, United Kingdom, and Milan, Italy). All patients had a confirmative diagnosis of RCD from histology. All patients were assessed by dietitians to ensure that they were on a GFD. Changes diagnostic of RCD I included persistent villous atrophy in the presence of CD3+, CD8+ intraepithelial lymphocytes (IELs) with polyclonal T-cell receptors (TCRs) [3]. RCD II patients had loss of surface CD3 and CD8 with monoclonality of TCRs [20,21]. RCD patients underwent the first and subsequent SBCEs to assess any changes in CD in view of persistent symptoms, or to look for complications related to RCD.

Patients with serology-negative CD had villous atrophy on duodenal histology at the time of diagnosis, but negative CD serology (endomysial antibody [EMA] and tissue transglutaminase antibody [TTG-IgA]). Other causes of villous atrophy, such as infective etiologies and medications, were excluded as per criteria defined in our previous study [22]. These patients initially responded to a GFD but eventually developed changes consistent with RCD.

Other data gathered as part of this study included: age, duration of disease, symptoms, CD serology (EMA and TTG-IgA) and Marsh score of duodenal histology at the time of SBCE, type of treatment given between SBCEs, human leukocyte antigen (HLA) DQ2, DQ8 status, and type of RCD (type I or II).

Duodenal histology

At least 4 biopsy specimens (including a duodenal bulb biopsy) were taken from the duodenum during gastroduodenoscopy according to current guidelines, at the time of SBCE [13,23]. Biopsies were fixed in formalin at the time of the gastroduodenoscopy. Specimens were then orientated and embedded in paraffin wax by the pathology department. Standard 3- μ m thick sections at 3 levels were stained with hematoxylin and eosin. All histological samples were reviewed by one of 2 expert histopathologists. Histology was classified according to the modified Marsh criteria in patients with CD [24].

Immunohistochemistry and flow cytometry were performed on all duodenal biopsies. The immunophenotype

of IELs in patients with RCD I was similar to that found in uncomplicated CD, staining positive for CD3 and CD8, and having polyclonal TCRs [3]. In those with RCD II, duodenal biopsies demonstrated aberrant IELs with loss of surface CD3 and CD8. There was also monoclonality of TCRs [20,21]. Whenever a null clone was identified, *TCR* gene rearrangement studies were carried out to exclude lymphoma.

Patients underwent repeat duodenal histology at the time of repeat SBCE as part of their follow-up of RCD, to exclude progression of disease from RCD I to RCD II and to rule out histological changes of lymphoma.

Small bowel capsule endoscopy

Each patient was asked to stay on clear fluids for 24 h before SBCE and to drink 2 L of polyethylene glycol the day before SBCE. All patients underwent SBCE using a Pillcam SB2 or SB3 (Medtronic, Minneapolis, USA) [25].

SBCEs were de-identified and reviewed by SBCE experts (with an experience of more than 200 capsules per year) in their center. Features of CD on SBCE were recorded, such as villous atrophy, fissuring of folds, mosaic pattern, scalloping, nodularity of mucosa, and ulcers [26,27]. The extent of abnormal SB mucosa and percentage extent of abnormal SB mucosa were calculated. For the purposes of this study, the extent of abnormal SB mucosa referred to SB mucosa with macroscopic features of CD, and the percentage extent of abnormal SB mucosa referred to the proportion of abnormal SB mucosa with respect to the total SB transit. Patients underwent repeat SBCEs as part of their follow-up during the disease course to rule out pre-malignant and malignant conditions [28,29].

Ethical considerations

The study protocol was approved by the Yorkshire and the Humber Research Ethics committee (IRAS 232382) and registered with the local research and development department of Sheffield Teaching Hospital NHS Foundation Trust (registration number STH 19998). The local Ethics Committee for Human Research in Milan approved the study protocol (approval number 2271). All SBCEs were de-identified. No additional consent was required for the use of de-identified videos as assessed and approved formally by the Research Ethics Committee.

Statistical analysis

Statistical analysis was carried out using SPSS version 23 (IBM Corp. Released 2015. IBM SPSS Statistics for Mac, Version 23.0. Armonk, NY: IBM Corp.). The Spearman correlation coefficient was used to determine the relationship between 2 continuous variables and the Pearson chi-square test for categorical variables. Mann-Whitney *U* and Kruskal-Wallis tests were used to determine the relationship between continuous and categorical variables. The Wilcoxon signed-

rank test was used to determine the correlation between 2 related continuous variables, such as extent of disease on subsequent SBCEs in the same patient.

Results

Sixty patients with RCD (40 female, 66.7%) were included in this study. All had a median CD duration of 4 years by the time they had their first SBCE. All patients were on a GFD since diagnosis. Six patients had underlying serology-negative CD and 2 patients were IgA deficient.

HLA DQ2 DQ8 status was available for 50 patients (83.3%), and it varied as follows in the population studied: 12 (24%) HLA DQ2 homozygous, 32 (64%) HLA DQ2 heterozygous, 3 (6%) DQ8 homozygous, 2 (4%) negative for DQ2 and DQ8, 1 (2%) HLA DQ2, and DQ8 heterozygous. The 2 patients who had negative HLA DQ2 and DQ8 heterodimers were positive for the following alleles: DRB1*04, DQA1*03:03, DQB1*03:01 and DQA1*01, DQA1*02; DQB1*03:03, DQB1*06.

Most patients had proximal SB involvement on both first (n=33, 55%) and second (n=38, 63%) SBCEs. Diffuse disease was found in 14 (23%) and 7 (12%) patients on first and second SBCE, respectively (Table 1). The median time between the first and second SBCEs was 17.5 (4-31) months and the median time between subsequent SBCEs was 12 (1-40) months.

Findings on SBCE according to symptoms

A significant number of patients were symptomatic when they had their first (n=45, 75%) and second (n=27, 45%) SBCE. In the rest of the patients, abnormal blood tests (e.g., iron deficiency anemia, vitamin B12, folate deficiency) prompted investigations including duodenal histology and SBCE. Two patients also had abnormal position emission tomography (PET) scan results. However, there was no correlation between the presence or absence of symptoms and the percentage extent of disease on first (P=0.377) or second (P=0.950) SBCE.

Correlation of serology with features of CD on SBCE

Median TTG-IgA values at first and second SBCE were 3.5 (0-300) U/mL and 1.75 (0-196) U/mL respectively. EMA was positive in 6 patients (n=27, 22.2%) and 4 patients (n=23,

17.4%) at first and second SBCE, respectively. There was no difference in the percentage of abnormal SB mucosa between patients with positive and negative EMA at first (P=0.696) and second (P=0.180) SBCE. TTG-IgA did not correlate with percentage of abnormal SB mucosa at first (Spearman's rho 0.070, P=0.662) or second (Spearman's rho 0.041, P=0.790) SBCE.

Correlation of histology with features of CD on SBCE

Most patients had histology of Marsh grade 3a or above at the time of their first (n=55, 93.2%) and second (n=47, 83.9%) SBCE (Table 2). Marsh grade of histology did not correlate with percentage of abnormal SB mucosa at first SBCE (Spearman's rho 0.113, P=0.434), but there was a degree of correlation between Marsh grade of histology and percentage of abnormal SB mucosa at second SBCE (Spearman's rho 0.528, P=0.001). Features of CD also did not correlate significantly with Marsh grade of histology, except for scalloping (32/55 Marsh 3a or above; P=0.049) and mosaic pattern (31/55 Marsh 3a or above; P=0.016) at second SBCE.

Correlation of CD serology and duodenal histology

There was no correlation between TTG-IgA and grade of histology at first SBCE (Spearman's rho 0.150, P=0.336) or second SBCE (Spearman's rho 0.026, P=0.865). There was also no difference in grade of histology according to EMA at first (P=0.584) or second (P=0.331) SBCE.

Stratification according to treatment given

Most patients received treatment for RCD (n=46, 76.7%) (P=0.227) (Table 3). There was no statistical difference in the percentage of abnormal SB mucosa between the first and second SBCE according to the type of treatment administered (RCD I P=0.952, RCD II P=0.056). Only 5 (n=24; 20.8%) and 3 (n=11; 27.2%) patients had escalation of therapy prior to undergoing a third and fourth SBCE, respectively.

Table 2 Marsh score of histology on duodenal biopsies at first and second small bowel capsule endoscopy

Histology (Marsh classification)	N (%) at first capsule endoscopy (total with histology n=59)	N (%) at second capsule endoscopy (total with histology n=56)
0	2 (3.4)	4 (7.1)
1	2 (3.4)	4 (7.1)
2	0	1 (1.8)
3a	14 (23.7)	15 (26.8)
3b	14 (23.7)	17 (30.4)
3c	27 (45.8)	15 (26.8)

Table 1 Extent of celiac disease on small bowel capsule endoscopy

Region	First capsule endoscopy N (%)	Second capsule endoscopy N (%)
Proximal (duodenal)*	33 (55)	38 (63)
Beyond proximal*	23 (38.3)	14 (24)
Normal	4 (7)	8 (13)

*1/3 of small bowel transit involved;

**more than 1/3 of small bowel transit involved

Comparison of SBCEs in patients with RCD types I and II

Most patients had RCD type I (n=37, 61.7%). Patients with RCD type II had more extensive disease than those with RCD type I on first (median 41.4% vs. 19.2%; P=0.004) and second (median 29.8% vs. 12.0%; P=0.016) SBCE. Villous atrophy was a prominent feature in patients with RCD type II on first (P=0.015) and second SBCE (P=0.001) (Supplementary Table 1).

More patients with RCD type I (n=18, 60%) than type II (n=8, 34.8%) had a percentage extent of affected SB mucosa that improved on the second SBCE (P=0.049). However, the improvement was not sustained in subsequent SBCEs.

Comparison of capsule endoscopies along disease course

All patients had at least 2 SBCEs. Twenty-four patients had at least a third SBCE. Overall, 26 patients (49.1%) had an improved percentage extent of abnormal SB mucosa on undergoing a second SBCE (median 27.6% vs. 18.1% P=0.007). However, the improvement was not sustained in subsequent SBCEs and there was no statistically significant difference between the first and the last SBCE (P=0.655) (Table 4). The improvement in percentage extent of disease between the first 2 SBCEs contrasted with repeat duodenal histology, which showed no overall improvement (P=0.062).

Complications in patients with RCD

Nine patients (15%) developed RCD-related complications. Five patients developed ulcerative jejunoileitis (Fig. 1). All

Table 3 Type of treatment administered to patients with refractory celiac disease (RCD) of different type

Type of treatment	RCD I N (%)	RCD II N (%)
Steroids	14 (37.8)	12 (52.2)
Immunosuppressants	8 (21.6)	4 (17.4)
Combination (immunosuppressants & steroids)	5 (13.5)	1 (4.3)
Cladribine	0	2 (8.7)
None	10 (27.0)	4 (17.4)

Table 4 Gastric, small bowel passage time and extent of disease on small bowel capsule endoscopy

Parameters	First capsule endoscopy (median, range)	Second capsule endoscopy (median, range)	P-value (first, second capsule)	Third capsule endoscopy (median, range)	P-value (second, third capsule)
Gastric passage time (min)	14 (1-219)	12 (1-300)	0.985	126 (90-126)	0.314
Small bowel passage time (min)	282 (114-550)	280 (89-600)	0.176	393.5 (307-480)	0.205
Time with abnormal small bowel mucosa (min)	68 (0-379)	39 (0-315)	0.071	205 (160-250)	0.91
Percentage of abnormal small bowel mucosa	27.6 (0-100)	18.1 (0-100)	0.007	55.5 (30-81)	0.306

changes were detected on SBCE. They received cladribine (1 patient), budesonide (2 patients), budesonide and cladribine (1 patient), azathioprine and methylprednisolone (1 patient). Three patients with RCD developed EATL. In one of these patients EATL was diagnosed on *post mortem* examination. This patient was not on treatment for RCD. In another patient, EATL was diagnosed on the third SBCE (Fig. 2) and confirmed by histological specimens obtained from the SB during single balloon enteroscopy a year following the diagnosis of CD. The patient was on budesonide to treat RCD. EATL was confirmed on imaging, including PET scan, in a third patient. He was on mycophenolate for RCD and was being managed with cladribine when the diagnosis of EATL was made. One patient developed cutaneous T-cell lymphoma 3 years from when she was diagnosed with CD. Her RCD was managed with mycophenolate and budesonide. She was given cladribine when she was diagnosed with lymphoma.

All patients who developed complications had underlying RCD II, except for 1 patient who developed cutaneous T-cell lymphoma. There was no statistical difference in percentage extent of disease at the first (P=0.960, 0.152%) and second (P=0.403, 0.910%) SBCEs between patients who developed or did not develop complications and had RCD type I or II, respectively.

Discussion

This is the largest, study to demonstrate the role of SBCE in the diagnosis and subsequent management of patients with RCD. It is the first study that portrays monitoring and the use of successive SBCEs in addition to duodenal histology during the disease course of patients with RCD. We also stratified differences in the features of CD in the SB according to symptoms, CD serology, histology, type of RCD, and type of treatment administered.

A few studies have reported on the use of SBCE in patients with RCD. The main focus in these studies was the exclusion of pre-malignant and malignant complications and reporting of CD features [28-31]. Most of these studies were small and therefore have had limited impact on the management of patients with RCD.

Previous studies have reported on the improvement in the extent of disease in the SB on SBCE in patients with uncomplicated CD following initiation of a GFD. There was an

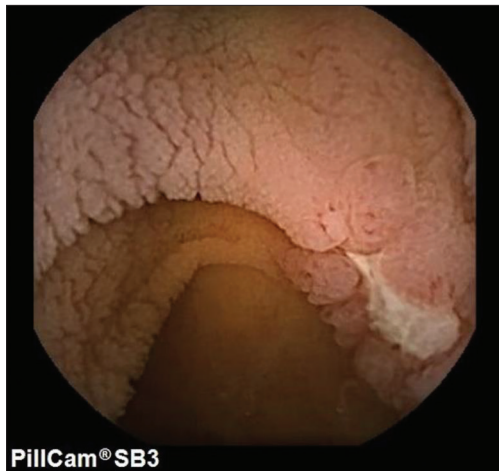


Figure 1 Image from small bowel capsule endoscopy of a patient with ulcerative jejunoileitis, showing fissuring and mosaic pattern of mucosa, and an ulcer

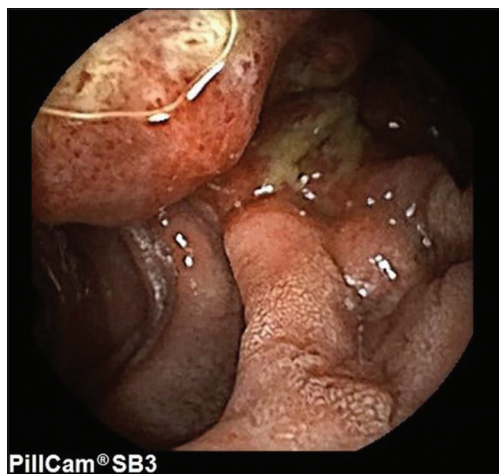

Figure 2 Enteropathy-associated T-cell lymphoma in a patient with refractory celiac disease

improvement in the extent of disease in 79% of patients following 6 months of GFD in a study by Murray *et al* [16]. A more recent study by Lidums *et al* showed an improvement in macroscopic villous atrophy in 12 patients with CD after 12 months of GFD [17]. We showed improvement in the extent of disease in a smaller group of patients with RCD following treatment with steroids and/or immunosuppressants in a previous study [19]. We have confirmed the same findings in this larger study carried out in 2 European centers. Interestingly, the same improvement noted in percentage extent of disease between the first and second SBCEs was not sustained during the third and subsequent SBCEs. This raises several questions about the effectiveness of current regimens used to treat patients with RCD and the timing interval between SBCEs. Even though the importance of repeating duodenal histology and SBCE in patients with RCD is recognized, no follow-up protocol has been proposed in the literature [13,32]. The poor prognosis of patients with RCD type II suggests that these patients should

be followed-up more closely than those with RCD type I [4,9]. More such studies are needed to provide evidence concerning the optimum time interval to follow-up these patients. We have also shown the lack of any long-term impact of steroids \pm immunosuppressants beyond a few months of treatment, highlighting the possibility that these patients are being undertreated and further escalation of therapy is not being considered. Only a small number of patients (n=5, 20.8%, and n=3, 27.2%) underwent a treatment addition or change prior to undergoing a third and fourth SBCE, respectively. This might have contributed to the lack of improvement in the extent of disease on SBCE in these patients.

Duodenal sampling during gastroduodenoscopy is important, as it confirms persistent villous atrophy and can identify aberrant IELs with monoclonality of TCRs [20,21]. Flow cytometry is also useful for evaluating aberrant IELs [33]. Duodenal histology unfortunately cannot provide valuable information on the extent of disease and RCD-related complications beyond the duodenum. These factors can instead be assessed using SBCE and dedicated SB imaging [28,29,34,35]. As in previous studies, our data did not show a correlation between Marsh grade of histology and extent of disease in the SB at the first SBCE [17,16]. Moreover, duodenal biopsies do not always show an improvement in the grade of histology when repeated after a time interval in patients with either uncomplicated [17] or complicated CD [19,36]. These arguments call for the use of gastroduodenoscopy to enable duodenal histology and SBCE, to be used together at intervals for surveillance of patients with RCD.

In our study, we failed to show a statistical correlation between CD symptoms and serology and extent of disease in the SB. Literature on these aspects has been contradictory to date. Two studies report on a positive qualitative association between extent of disease on SBCE and symptomatology in patients with CD [37,38]. A study by Lidums *et al* correlated the extent of affected SB with an improvement in the symptom score following a GFD. However, the same study was unable to demonstrate a correlation between extent of disease and symptomatology at baseline [17]. Another study by Murray *et al* failed to confirm this association [16]. The same study, also demonstrated more extensive disease in patients with positive EMA and a positive correlation with anti-TTG in 38 patients [16]. Findings from these studies and evidence from the literature suggest that follow-up and further investigations of patients with RCD should be independent of their symptoms and CD serology.

From the literature, we know that patients with RCD II have a more severe disease pattern than patients with RCD type I. They have a worse 5-year survival (45-58%) compared to those with RCD I (80-96%) [4,9]. Patients with RCD II often require stronger therapeutic agents than patients with RCD type I, such as cladribine or anti-interleukin 15 monoclonal antibody [39,40]. Refractoriness to treatment with immunosuppressants is more often described in patients with RCD type II than type I [41-44]. Patients with RCD type II had more extensive mucosal changes than those with RCD type I. This is consistent with the findings described in a smaller study by Barret *et al* [30]. Patients with RCD type I showed greater

improvement on second SBCE than those with RCD type II. Both the findings from our study and evidence from the literature reflect on the severity of disease equating to extent of disease, which so far has not been well described.

In this study, 6 patients had negative serology. Although RCD has predominantly been studied in patients with underlying serology-positive CD (at the time of diagnosis), complications can also occur in patients with serology-negative CD who have responded to a GFD initially, and in whom the clinical disease course resembles that of CD patients [22,45].

Two patients in this study encoded neither DQ2 nor DQ8 heterodimers. This is reported to exist in the literature in up to 2% of patients with CD [46-48]. For the few patients who are HLA DQ2, DQ8 negative, there is no clear association with any other DQ molecule. In these patients, the diagnosis of CD is based on serology, duodenal villous atrophy and response to a GFD.

Although SBCE can be used to diagnose pre-malignant and malignant conditions, as demonstrated in this study, the extent of disease in the SB does not predict those likely to develop further complications. SBCE is particularly useful in patients with the pre-malignant condition ulcerative jejunoileitis, where the superficial mucosal changes are unlikely to be picked up on SB imaging.

One of the limitations of this study was a small number of patients in each subgroup, making subgroup analysis more difficult to perform. However, in comparison to the available literature, this is the largest study of its kind and the only study that provides temporal follow up of SB mucosal changes in a cohort of RCD patients along their course of disease [4,28-30,34,35,36,39,40,42,44,49-59]. Both centers included in this study are tertiary centers for the management of patients with CD. The retrospective nature of this study resulted in some missing data, such as not all patients having duodenal histology taken and CD serology measured at the time that they underwent SBCE. All patients underwent at least 2 SBCEs. However, the number of patients who underwent subsequent SBCEs was small. This probably affected the statistical analysis of data involving third and subsequent SBCEs. Another limitation is the lack of standardization of reporting and the absence of prior interobserver agreement studies between reviewers from both centers. However, reviewers from both centers were international SBCE experts with experience in reviewing CD videos.

In conclusion, this study suggests that the extent of disease can be assessed on sequential SBCEs along the course of disease in patients with RCD. Whereas histology gives information on aberrant IELs, SBCE can help assess mucosal healing and rule out pre-malignant and malignant complications. However, disease extent in the SB was not predictive of complications, while improvement in the disease extent was not sustained on sequential SBCEs. Therefore, the use of SBCE in the clinical management of patients with RCD remains exploratory, and more such studies are required before its use is advocated routinely in these patients. Findings in this study suggest that patients with RCD type II suffered from more extensive disease and were less likely to improve on repeat SBCE compared to those with type I disease. This reflects on the poorer prognosis and higher likelihood of complications in patients with RCD type II described in the literature.

Summary Box

What is already known:

- Refractory celiac disease (RCD) can be associated with the development of pre-malignant and malignant conditions
- Patients with RCD require regular monitoring to rule out disease progression and development of complications

What the new findings are:

- Small bowel capsule endoscopy (SBCE) can be useful for comparing the extent of disease following the initiation of treatment
- Patients with RCD type II had more extensive disease than those with RCD type I on SBCE
- Patients with RCD type I tended to show a greater improvement in the percentage of abnormal small bowel involved on repeat SBCE compared to those with RCD type II

References

1. Rowinski SA, Christensen E. Epidemiologic and therapeutic aspects of refractory coeliac disease - a systematic review. *Dan Med J* 2016;**63**:A5307.
2. Ilus T, Kaukinen K, Virta LJ, et al. Refractory coeliac disease in a country with a high prevalence of clinically-diagnosed coeliac disease. *Aliment Pharmacol Ther* 2014;**39**:418-425.
3. Malamut G, Afchain P, Verkarre V, et al. Presentation and long-term follow-up of refractory celiac disease: comparison of type I with type II. *Gastroenterology* 2009;**136**:81-90.
4. Rubio-Tapia A, Kelly DG, Lahr BD, Dogan A, Wu TT, Murray JA. Clinical staging and survival in refractory celiac disease: a single center experience. *Gastroenterology* 2009;**136**:99-107.
5. Eigner W, Bashir K, Primas C, et al. Dynamics of occurrence of refractory coeliac disease and associated complications over 25 years. *Aliment Pharmacol Ther* 2017;**45**:364-372.
6. Volta U, Caio G, Stanghellini V, De Giorgio R. The changing clinical profile of celiac disease: a 15-year experience (1998-2012) in an Italian referral center. *BMC Gastroenterol* 2014;**14**:194.
7. Woodward J. Improving outcomes of refractory celiac disease - current and emerging treatment strategies. *Clin Exp Gastroenterol* 2016;**9**:225-236.
8. Liu H, Brais R, Lavergne-Slove A, et al. Continual monitoring of intraepithelial lymphocyte immunophenotype and clonality is more important than snapshot analysis in the surveillance of refractory coeliac disease. *Gut* 2010;**59**:452-460.
9. Al-Toma A, Verbeek WH, Hadithi M, von Blomberg BM, Mulder CJ. Survival in refractory coeliac disease and enteropathy-associated T-cell lymphoma: retrospective evaluation of single-centre experience. *Gut* 2007;**56**:1373-1378.
10. Daum S, Ipczynski R, Schumann M, Wahnschaffe U, Zeitz M, Ullrich R. High rates of complications and substantial mortality in both types of refractory sprue. *Eur J Gastroenterol Hepatol*

- 2009;**21**:66-70.
11. Al-Toma A, Volta U, Auricchio R, et al. European Society for the Study of Coeliac Disease (ESsCD) guideline for coeliac disease and other gluten-related disorders. *United European Gastroenterol J* 2019;**7**:583-613.
 12. Rubio-Tapia A, Hill ID, Kelly CP, Calderwood AH, Murray JA; American College of Gastroenterology. ACG clinical guidelines: diagnosis and management of celiac disease. *Am J Gastroenterol* 2013;**108**:656-676; quiz 677.
 13. Ludvigsson JF, Bai JC, Biagi F, et al; British Society of Gastroenterology. Diagnosis and management of adult coeliac disease: guidelines from the British Society of Gastroenterology. *Gut* 2014;**63**:1210-1228.
 14. Al-Bawardy B, Barlow JM, Vasconcelos RN, et al. Cross-sectional imaging in refractory celiac disease. *Abdom Radiol (NY)* 2017;**42**:389-395.
 15. Iddan G, Meron G, Glukhovskiy A, Swain P. Wireless capsule endoscopy. *Nature* 2000;**405**:417.
 16. Murray JA, Rubio-Tapia A, Van Dyke CT, et al. Mucosal atrophy in celiac disease: extent of involvement, correlation with clinical presentation, and response to treatment. *Clin Gastroenterol Hepatol* 2008;**6**:186-193.
 17. Lidums I, Teo E, Field J, et al. Capsule endoscopy: a valuable tool in the follow-up of people with celiac disease on a gluten-free diet. *Clin Transl Gastroenterol* 2011;**2**:e4.
 18. Branchi F, Ferretti F, Orlando S, et al. Small-bowel capsule endoscopy in patients with celiac disease, axial vs. lateral/panoramic view: results from a prospective randomized trial. *Dig Endosc* 2019;**32**:778-784.
 19. Chetcuti Zammit S, Sanders DS, Cross SS, Sidhu R. Capsule endoscopy in the management of refractory coeliac disease. *J Gastrointest Liver Dis* 2019;**28**:15-22.
 20. Husby S, Koletzko S, Korponay-Szabó IR, et al; European Society for Pediatric Gastroenterology, Hepatology, and Nutrition. European Society for Pediatric Gastroenterology, Hepatology, and Nutrition guidelines for the diagnosis of coeliac disease. *J Pediatr Gastroenterol Nutr* 2012;**54**:136-160.
 21. Cellier C, Patey N, Mauvieux L, et al. Abnormal intestinal intraepithelial lymphocytes in refractory sprue. *Gastroenterology* 1998;**114**:471-481.
 22. Chetcuti Zammit S, Schieppati A, Aziz I, Kurien M, Sanders DS, Sidhu R. Use of small-bowel capsule endoscopy in cases of equivocal celiac disease. *Gastrointest Endosc* 2020;**91**:1312-1321.e2.
 23. Pais WP, Duerksen DR, Pettigrew NM, et al. How many duodenal biopsy specimens are required to make a diagnosis of celiac disease? *Gastrointest Endosc* 2008;**67**:1082-1087.
 24. Oberhuber G, Granditsch G, Vogelsang H. The histopathology of coeliac disease: time for a standardized report scheme for pathologists. *Eur J Gastroenterol Hepatol* 1999;**11**:1185-1194.
 25. Zwinger LL, Siegmund B, Stroux A, et al. CapsoCam SV-1 Versus PillCam SB 3 in the detection of obscure gastrointestinal bleeding: results of a prospective randomized comparative multicenter study. *J Clin Gastroenterol* 2019;**53**:e101-e106.
 26. Tursi A, Brandimarte G, Giorgetti GM, Gigliobianco A. Endoscopic features of celiac disease in adults and their correlation with age, histological damage, and clinical form of the disease. *Endoscopy* 2002;**34**:787-792.
 27. Biagi F, Rondonotti E, Campanella J, et al. Video capsule endoscopy and histology for small-bowel mucosa evaluation: a comparison performed by blinded observers. *Clin Gastroenterol Hepatol* 2006;**4**:998-1003.
 28. Daum S, Wahnschaffe U, Glasenapp R, et al. Capsule endoscopy in refractory celiac disease. *Endoscopy* 2007;**39**:455-458.
 29. Culliford A, Daly J, Diamond B, Rubin M, Green PH. The value of wireless capsule endoscopy in patients with complicated celiac disease. *Gastrointest Endosc* 2005;**62**:55-61.
 30. Barret M, Malamut G, Rahmi G, et al. Diagnostic yield of capsule endoscopy in refractory celiac disease. *Am J Gastroenterol* 2012;**107**:1546-1553.
 31. Elli L, Casazza G, Locatelli M, et al. Use of enteroscopy for the detection of malignant and premalignant lesions of the small bowel in complicated celiac disease: a meta-analysis. *Gastrointest Endosc* 2017;**86**:264-273.
 32. Pennazio M, Spada C, Eliakim R, et al. Small-bowel capsule endoscopy and device-assisted enteroscopy for diagnosis and treatment of small-bowel disorders: European Society of Gastrointestinal Endoscopy (ESGE) Clinical Guideline. *Endoscopy* 2015;**47**:352-376.
 33. Verbeek WH, Goerres MS, von Blomberg BM, et al. Flow cytometric determination of aberrant intra-epithelial lymphocytes predicts T-cell lymphoma development more accurately than T-cell clonality analysis in refractory celiac disease. *Clin Immunol* 2008;**126**:48-56.
 34. Tomba C, Sidhu R, Sanders DS, et al. Celiac disease and double-balloon enteroscopy: what can we achieve?: the experience of 2 European tertiary referral centers. *J Clin Gastroenterol* 2016;**50**:313-317.
 35. Van Weyenberg SJ, Bouman K, Jacobs MA, et al. Comparison of MR enteroclysis with video capsule endoscopy in the investigation of small-intestinal disease. *Abdom Imaging* 2013;**38**:42-51.
 36. Brar P, Lee S, Lewis S, Egbuna I, Bhagat G, Green PH. Budesonide in the treatment of refractory celiac disease. *Am J Gastroenterol* 2007;**102**:2265-2269.
 37. Petroniene R, Dubcenco E, Baker JP, et al. Given capsule endoscopy in celiac disease: evaluation of diagnostic accuracy and interobserver agreement. *Am J Gastroenterol* 2005;**100**:685-694.
 38. Rondonotti E, Spada C, Cave D, et al. Video capsule endoscopy in the diagnosis of celiac disease: a multicenter study. *Am J Gastroenterol* 2007;**102**:1624-1631.
 39. Al-Toma A, Goerres MS, Meijer JW, et al. Cladribine therapy in refractory celiac disease with aberrant T cells. *Clin Gastroenterol Hepatol* 2006;**4**:1322-1327; quiz 1300.
 40. Cellier C, Bouma G, van Gils T, et al. 616 - AMG 714 (Anti-IL-15 MAB) halts the progression of aberrant intraepithelial lymphocytes in refractory celiac disease type II (RCD-II): a phase 2a, randomized, double-blind, placebo-controlled study evaluating AMG 714 in adult patients with RCD-II/Pre-EATL. *Gastroenterology* 2018;**6** Suppl 1:S-129-S-130.
 41. Daum S, Ipczynski R, Heine B, Schulzke JD, Zeitz M, Ullrich R. Therapy with budesonide in patients with refractory sprue. *Digestion* 2006;**73**:60-68.
 42. Tack GJ, Verbeek WH, Al-Toma A, et al. Evaluation of Cladribine treatment in refractory celiac disease type II. *World J Gastroenterol* 2011;**17**:506-513.
 43. Cellier C, Delabesse E, Helmer C, et al. Refractory sprue, coeliac disease, and enteropathy-associated T-cell lymphoma. French Coeliac Disease Study Group. *Lancet* 2000;**356**:203-208.
 44. Goerres MS, Meijer JW, Wahab PJ, et al. Azathioprine and prednisone combination therapy in refractory coeliac disease. *Aliment Pharmacol Ther* 2003;**18**:487-494.
 45. Ríos León R, Crespo Pérez L, Rodríguez de Santiago E, et al. Genetic and flow cytometry analysis of seronegative celiac disease: a cohort study. *Scand J Gastroenterol* 2019;**54**:563-570.
 46. Karel K, Louka AS, Moodie SJ, et al; European Genetics Cluster on Celiac Disease. HLA types in celiac disease patients not carrying the DQA1*05-DQB1*02 (DQ2) heterodimer: results from the European Genetics Cluster on Celiac Disease. *Hum Immunol* 2003;**64**:469-477.
 47. Pietzak MM, Schofield TC, McGinniss MJ, Nakamura RM. Stratifying risk for celiac disease in a large at-risk United States

- population by using HLA alleles. *Clin Gastroenterol Hepatol* 2009;**7**:966-971.
48. Megiorni F, Mora B, Bonamico M, et al. HLA-DQ and risk gradient for celiac disease. *Hum Immunol* 2009;**70**:55-59.
49. Rolny P, Sigurjonsdottir HA, Remotti H, et al. Role of immunosuppressive therapy in refractory sprue-like disease. *Am J Gastroenterol* 1999;**94**:219-225.
50. Mulder CJ, Wahab PJ, Meijer JW, Metselaar E. A pilot study of recombinant human interleukin-10 in adults with refractory coeliac disease. *Eur J Gastroenterol Hepatol* 2001;**13**:1183-1188.
51. Gillett HR, Arnott ID, McIntyre M, et al. Successful infliximab treatment for steroid-refractory celiac disease: a case report. *Gastroenterology* 2002;**122**:800-805.
52. Mauriño E, Niveloni S, Cherniavsky A, et al. Azathioprine in refractory sprue: results from a prospective, open-label study. *Am J Gastroenterol* 2002;**97**:2595-2602.
53. Turner SM, Moorghen M, Probert CS. Refractory coeliac disease: remission with infliximab and immunomodulators. *Eur J Gastroenterol Hepatol* 2005;**17**:667-669.
54. Olausson RW, Løvik A, Tollefsen S, et al. Effect of elemental diet on mucosal immunopathology and clinical symptoms in type I refractory celiac disease. *Clin Gastroenterol Hepatol* 2005;**3**:875-885.
55. Al-toma A, Visser OJ, van Roessel HM, et al. Autologous hematopoietic stem cell transplantation in refractory celiac disease with aberrant T cells. *Blood* 2007;**109**:2243-2249.
56. Jamma S, Leffler DA, Dennis M, et al. Small intestinal release mesalamine for the treatment of refractory celiac disease type I. *J Clin Gastroenterol* 2011;**45**:30-33.
57. Tack GJ, Wondergem MJ, Al-Toma A, et al. Auto-SCT in refractory celiac disease type II patients unresponsive to cladribine therapy. *Bone Marrow Transplant* 2011;**46**:840-846.
58. Tack GJ, van Asseldonk DP, van Wanrooij RL, van Bodegraven AA, Mulder CJ. Tioguanine in the treatment of refractory coeliac disease--a single centre experience. *Aliment Pharmacol Ther* 2012;**36**:274-281.
59. Mukewar SS, Sharma A, Rubio-Tapia A, Wu TT, Jabri B, Murray JA. Open-capsule budesonide for refractory celiac disease. *Am J Gastroenterol* 2017;**112**:959-967.

Supplementary material

Supplementary Table 1 Features of celiac disease on small bowel capsule endoscopy in patients with refractory celiac disease type I and II

SBCE	Features of celiac disease	Refractory celiac disease type n (%)		P value (significance)
		Type I	Type II	
First SBCE	Villous atrophy	22 (61.1)	21 (91.3)	0.015
	Scalloping	24 (66.7)	18 (78.3)	0.391
	Mosaic pattern	20 (54.1)	15 (65.2)	0.432
	Fissuring	5 (13.5)	3 (13.0)	0.958
	Nodularity	1 (2.8)	1 (4.5)	0.720
	Ulcers	7 (18.9)	2 (8.7)	0.460
Second SBCE	Villous atrophy	14 (37.8)	19 (82.6)	0.001
	Scalloping	19 (52.8)	19 (82.6)	0.026
	Mosaic pattern	20 (55.6)	15 (65.2)	0.589
	Fissuring	15 (41.7)	4 (17.4)	0.085
	Nodularity	4 (14.3)	1 (5.3)	0.396
	Ulcers	6 (16.7)	3 (13.0)	0.706