

Endoscopic clipping for gastrointestinal bleeding: emergency and prophylactic indications

Amaury Teixeira Xavier^{a,c}, Júlia Faria Campos^{a,c}, Lucinda Robinson^b, Elmar José Moreira Lima^c,
Luiz Claudio Miranda da Rocha^d, Vitor Nunes Arantes^a

Federal University of Minas Gerais, Belo Horizonte, Brazil; Flinders Medical Centre, Adelaide, Australia; Military Hospital of Minas Gerais, Belo Horizonte, Brazil; Mater Dei Hospital, Belo Horizonte, Brazil

Abstract

Endoscopic clipping has become a common practice among endoscopists. Several models are available, most frequently being introduced via the working channel of the endoscope (through-the-scope); however, larger clips can also be mounted onto the distal tip of the endoscope (over-the-scope). The main indications for endoclip placement include providing effective mechanical hemostasis for bleeding lesions and allowing endoscopic closure of gastrointestinal perforations. Endoclips can also be used prophylactically after endoscopic resection; however, this practice is still controversial. This review discusses the main indications for endoscopic clipping in the esophagus, stomach, duodenum and colon to manage acute bleeding lesions, and the criteria to be used in the prevention of delayed post-polypectomy bleeding.

Keywords Endoclip, mechanical hemostasis, gastrointestinal bleeding, prophylaxis, post-polypectomy

Ann Gastroenterol 2020; 33 (5): 1-8

Introduction

The endoscopic clip, endoclip or hemoclip, was first introduced in 1975 by Hayashi *et al* in the treatment of gastrointestinal bleeding [1]. Endoclips are metallic devices available in a variety of sizes, of which the majority are rotatable with reopening and closing capabilities, facilitating precise deployment. The clip achieves hemostasis by clamping the vessel and/or approximating the edges of the lesion, producing mechanical compression without causing tissue injury [2,3]. Retention time is variable, and a clip may remain at the site of application for 1-3 weeks after placement [4]. In general, endoclips should be applied in a transverse direction to the vessel

and sequentially applied in a zipper fashion to repair a mucosal defect. Endoclips are easy to handle, effective and safe [5].

Some examples of available through-the-scope (TTS) models include: QuickClip (Olympus, Japan) in sizes 8, 11 or 12 mm; Resolution (Boston Scientific, USA) 11 mm; Instinct (Cook Medical, Ireland) 16 mm; DuraClip (Conmed, USA) 11 and 16 mm; and Sureclip (Micro-Tech, USA) 8, 11 and 16 mm. Also available is the over-the-scope clip (OTSC) accessory (Ovesco Endoscopy AG, Germany; Padlock Clip Aponos Medical, USA), whose release is similar to an elastic band ligation procedure. The OTSC is mostly indicated for large and fibrotic ulcers, rescue therapy in non-variceal upper gastrointestinal bleeding, fistulas, perforations and dehiscence of anastomoses, or in other circumstances in which treatment with a TTS approach is difficult or fails [6,7].

This review addresses the main emergency indications for endoclip usage, such as gastrointestinal hemorrhage, as well as prophylactic indications, including prevention of delayed bleeding and perforation after endoscopic resection. This review will not evaluate the use of the clip as a traction method for submucosal dissection or in surgical complications (e.g., fistulas or bleeding anastomoses).

^aEndoscopy Unit, Alfa Institute of Gastroenterology, Clinics Hospital, Federal University of Minas Gerais, Belo Horizonte, Brazil (Amaury Teixeira Xavier, Júlia Faria Campos, Vitor Nunes Arantes); ^bDepartment of Medicine, Flinders Medical Centre, Adelaide, Australia (Lucinda Robinson); ^cEndoscopy Unit, Military Hospital of Minas Gerais, Belo Horizonte, Brazil (Amaury Teixeira Xavier, Júlia Faria Campos, Elmar José Moreira Lima); ^dMater Dei Hospital, Belo Horizonte, Brazil (Luiz Claudio Miranda da Rocha)

Conflict of Interest: None

Correspondence to: Amaury Teixeira Xavier, Universidade Federal de Minas Gerais, Medicine, Avenida Professor Alfredo Balena, Santa Efigenia, Instituto Gastroenterology, Belo Horizonte, Minas Gerais, 30130-100 Brazil, e-mail: amaury201@yahoo.com.br

Received 4 May 2020; accepted 26 June 2020;
published online 30 July 2020

DOI: <https://doi.org/10.20524/aog.2020.0526>

© 2020 Hellenic Society of Gastroenterology

Endoclips in the emergency setting

Bleeding peptic ulcer

Bleeding peptic ulcers are the main cause of upper gastrointestinal bleeding [8]. Early endoscopy should be

www.annalsgastro.gr

performed within 24 h of the patient's admission [9-11]. Endoscopic intervention reduces the risk of rebleeding and the requirement for surgery, and improves mortality. Endoscopic therapy options include: injectable methods (dilute epinephrine solution, ethanol, ethanolamine and polidocanol); thermocoagulation methods (heater probes, electrocautery probes, coagulation forceps and argon plasma coagulation); and mechanical hemostasis (clipping and elastic banding). Established indications for endoscopic hemostasis include actively bleeding ulcers and ulcers with a non-bleeding visible vessel (Forrest classes Ia, Ib and IIa). Ulcers with an adherent clot (Forrest IIb) should receive individualized management, and may or may not be suitable for endoscopic hemostasis [12].

Epinephrine injection alone is less effective than thermocoagulation or clipping as monotherapy [9,10]. A randomized controlled trial (RCT) with 47 patients showed that endoscopic clipping as monotherapy is comparable to epinephrine injection combined with thermocoagulation via a bipolar cautery probe [13]. A meta-analysis of prospective RCTs reinforced that epinephrine injection alone results in higher rates of rebleeding and requirement for surgical intervention compared with clipping as monotherapy, and also failed to show a clear benefit of endoclippping compared to thermocoagulation [14,15]. Another RCT showed that monopolar hemostatic forceps with soft coagulation, a relatively new contact thermal method, was associated with a higher hemostasis success rate, lower recurrent bleeding rate and a shorter procedure time compared to endoclip methods [16]. According to the European Society for Gastrointestinal Endoscopy (ESGE) guidelines, endoclip can be used as monotherapy for ulcers with a non-bleeding visible vessel. In ulcers with active bleeding, combination therapy (injection of epinephrine in conjunction with either a mechanical or thermal method) is recommended [10].

Rates of hemostatic success using endoclip technology vary from 85-100% and a failure rate of up to 20% has been described in those patients with chronic ulcers [2]. Other factors that increase the difficulty of endoclip placement and predict failure of hemostasis include: large ulcers (over 2 cm), a large non-bleeding visible vessel within the lesion, ulcers located in the lesser gastric curvature or in the posterior duodenal wall, and excessive blood in the stomach [12].

Mallory-Weiss tear

A Mallory-Weiss tear or Mallory-Weiss syndrome (MWS) is a laceration of the mucosa at the esophagogastric junction, caused by repetitive vomiting, usually treated conservatively [17]. Endoscopic treatment is indicated in cases of active bleeding on examination or presence of a deep laceration, and may consist of injection of dilute epinephrine, thermocoagulation or placement of endoclips [9]. A study published in 2016, including 168 patients with MWS, demonstrated that endoclip-based therapy and endoscopic band ligation achieved higher success rates than injection therapy in preventing rebleeding (96.4%, 88.9% and 71.4%, respectively, $P=0.013$) [18]. Although there are no RCTs demonstrating superiority of one

particular method over another [9], endoscopic clipping causes less tissue damage, reducing the risks of tissue necrosis and perforation [19]. Despite this, in a prospective RCT, Young-Seok *et al* demonstrated that endoscopic band ligation and endoclippping are equally effective and safe for the management of active bleeding in patients with MWS [20].

Dieulafoy's lesion

Dieulafoy's lesion is a vascular abnormality in which there is exposure of a dilated submucosal vessel that erodes, causing massive bleeding. These lesions are relatively rare, usually located in the stomach and duodenum, and have a high risk of rebleeding (19%) [21]. Mechanical hemostasis with endoclippping is superior to injection methods and is considered effective for both the control of acute bleeding and reducing the rate of rebleeding [22]. In addition, the metal clip has the advantage of marking the lesion site in the event of rebleeding and subsequent need for further endoscopic, radiological or surgical intervention [9]. Mechanical methods, including clipping or elastic band ligation, should be the first choice in this type of lesion [21], although there is no consensus regarding their superiority in relation to thermocoagulation. A meta-analysis that included 5 studies compared primary hemostasis and rebleeding rates in 162 patients with upper gastrointestinal bleeding caused by a Dieulafoy's lesion treated with endoscopic band ligation ($n=75$) or endoclippping ($n=87$). The results showed that both mechanical methods achieved similar rates of primary hemostasis (0.96 vs. 0.91, relative risk [RR] 1, 95% confidence interval [CI] 0.96-1.05) and rebleeding (0.06 vs. 0.17, RR 0.37, 95%CI 0.12-1.09) [23]. ESGE guidelines recommend that endoscopic hemostasis of these lesions should be achieved using thermal or mechanical methods, either alone or in combination with epinephrine injection [10].

Colonic diverticular bleeding

Arterial diverticular bleeding typically occurs at the base or edge of the diverticulum and presents as painless hematochezia. Diverticular bleeding is the most common cause of lower gastrointestinal bleeding. Colonoscopy with endoscopic hemostasis is safe and effective in 87-100% of cases [24]. Patients with diverticular bleeding are candidates for endoscopic treatment if there is active bleeding, a non-bleeding visible vessel or adherent clot. If untreated, these bleeding stigmata predict a high risk for rebleeding (84%, 60% and 43%, respectively) [25]. Endoclippping and thermocoagulation are effective treatments for diverticular bleeding; however, mechanical therapy is preferable for vessels located at the base of the diverticulum, which carry a lower risk of perforation [26]. Direct clipping onto the vessel, when feasible, is the treatment of choice in colonic diverticular hemorrhage. The clip may also serve as an anatomical marker for angiography or surgery in the case of recurring bleeding. If clipping is not possible, elastic band ligation is an acceptable

alternative [27]. A recent cohort study enrolling 108 patients evaluated the risk of recurrent bleeding up to a year post elastic band ligation versus endoscopic clipping. The authors concluded that band ligation had better outcomes than clipping during long-term follow up [28]. There are no RCTs available that compared these 2 endoscopic modalities.

OTSC

The OTSC, like a “bear-trap”, is a novel endoscopic clipping device that has generally been used in the setting of recurrent or refractory bleeding that cannot be controlled by TTS endoclips [29]. Kirschniak *et al* demonstrated the clinical utility of the OTSC system for the first time in 2007 to close a gastric perforation [30]. Its main advantages include the strong and sustained compression forces that can be exerted and the capacity to capture a larger volume of tissue compared with standard endoclips [31]. Other applications reported in retrospective studies and case series include the closure of perforations, fistulas and anastomotic leaks [32-34].

In a prospective multicenter trial, 67 patients with recurrent peptic ulcer bleeding following initially successful hemostasis were enrolled and randomized, with 34 receiving standard therapy (TTS clips or thermal therapy plus injection with diluted adrenaline) and 33 receiving OTSC. Treatment with OTSC was significantly superior to standard therapy in terms of bleeding control. Clinical success (i.e., no further bleeding) was also significantly higher in the OTSC versus the standard therapy group (84.9% vs. 42.4%; $P=0.001$), with a relative risk reduction for further bleeding of 73.6%. There were no significant differences between the groups in mortality or requirement for surgical or angiographic salvage therapy [35]. A recent review study of 1517 cases summarized the clinical results of 30 articles. The average clinical success rate of the OTSC for refractory bleeding was 85% (473/559 cases), 85% (297/351) for perforation, 52% (200/388) for fistulas, and 66% (64/97) for anastomotic dehiscence [7]. A disadvantage of this device in active bleeding is that the endoscope must be removed to mount the OTSC system distally, with reintroduction required to deploy the clips, potentially impairing a good view of the target lesion. Some important clinical studies reviewing endoclip treatment for bleeding lesions in the gastrointestinal tract are listed in Table 1.

Prophylactic use of endoclips

Endoclips have been widely used to prevent complications such as delayed bleeding or perforation resulting from endoscopic resection. Delayed bleeding is defined as any clinically significant bleeding occurring within 30 days post procedure. Although there is controversy regarding the cost-benefit relationship of this practice, recent publications and guidelines have encouraged the use of endoclip placement as a prophylactic measure. Most studies have evaluated the

prophylactic use of endoclips in the colon, given the increase in the number of screening colonoscopies, polypectomies and mucosectomies performed.

Esophagus and stomach

The use of the endoclip in resection of esophageal and gastric lesions is justified in situations post endoscopic resection where an active uncontrolled bleeding vessel or non-bleeding protuberant vessel is present at the resection site, or in suspected perforation. In other situations, such as patients on anticoagulation or antiplatelet therapy, in the presence of portal hypertension [36] or for lesions with a large pedicle or with large vessels, prophylactic endoclippping can also be considered in the esophagus or stomach. There are currently no high quality controlled clinical trials that recommend the preventive use of endoclips in these segments.

Duodenum

Duodenal polyps or lesions, although rare, are increasingly being identified by endoscopy. The most frequent duodenal lesions are lipomas, gastrointestinal stromal tumors, neuroendocrine tumors, Brunner's gland hamartomas, Peutz-Jeghers polyps and adenomas [37]. Endoscopic resection of duodenal lesions is technically more difficult and has a higher risk of immediate and delayed bleeding complications (14%) and perforation (1.9%) compared to elsewhere in the gastrointestinal tract. Most studies involve resection of superficial non-ampullary epithelial tumors (0.1-0.4%) [38]. Duodenal polypectomy or mucosectomy is technically challenging, because of the narrow lumen, the presence of peristalsis, loop formation and difficulty in device positioning, especially for lesions distal to the ampulla of Vater. Other contributing factors that render treatment difficult include the presence of a thinner *muscularis propria* layer, an extensive vascular plexus supplied by the gastroduodenal artery and the pancreatoduodenal arch, and the presence of Brunner's glands in the submucosa, which may hinder the lifting of the target lesion during catheter injection [37,38].

Multiple biopsies of superficial duodenal lesions should be avoided, as the resulting fibrosis may impair the lifting and removal of the target lesion during endoscopic treatment [39]. In the case of endoscopic therapy in the duodenum, polypectomy may be indicated in lesions ≤ 10 mm, and mucosectomy in lesions >10 mm.

The effect of prophylactic mucosal closure after endoscopic resection is unclear. A study of 91 lesions enrolling 91 patients who underwent endoscopic resection for superficial non-ampullary duodenal tumors investigated the efficacy of prophylactic clipping for the prevention of late complications. Individuals were allocated to either an immediate clipping group or to a non-clipping group. Delayed bleeding occurred in 1 patient (2.1%) and delayed perforation occurred in 1 patient (2.1%) within the clipping group, whereas within the

Table 1 Relevant clinical studies of endoclip treatment for bleeding lesions in the gastrointestinal tract

Study	Type of study	Treatment/ Sample size	Bleeding source	Initial hemostasis	Rebleeding	Surgery/ Embolisation	Death
Sung <i>et al</i> 2007 [14]	Meta-analysis	HC x INJ (8 RCTs, n=446)	Ulcers and Dieulafoy's	95.9x 95.1% RR 1.01 (95%CI 0.96-1.06)	9.5x 19.6% RR 0.49 (95%CI 0.3-0.7)	2.3x 7.4% RR 0.37 (95%CI 0.15-0.9)	2.7x 1.8% RR 1.45 (95%CI 0.44-4.74)
		HC+INJ x INJ (7 RCTs, n=502)		96x 96% RR 1 (95%CI 0.95-1.05)	8.3-18% RR 0.47 (95%CI 0.28-0.78)	1.3 x 6.3% RR 0.23 (95%CI 0.08-0.7)	2.5x 1.9% RR 1.23 (95%CI 0.45- 3.37)
		HC x Ther (4 RCTs, n=333)		88.7 x 94% RR 0.94 (95%CI 0.84-1.07)	7.1x 13.3 RR 0.65 (95%CI 0.21-2.02)	4.2x 4.8% RR 0.84 (95%CI 0.32-2.24)	3.6 x 3.6% RR 0.96 (95%CI 0.34- 2.7)
Barakat <i>et al</i> 2016 [15]	Meta-analysis	HC x INJ (6 RCTs, n=641)	Ulcers	RD 0.01 (95%CI -0.02 to 0.04)	RD -0.13 (95%CI -0.19 to -0.08) NNT 7	RD -0.05 (95%CI -0.09 to -0.01). NNT 20	RD 0.02 (95%CI -0.01 to 0.06)
		HC+INJ x INJ (4 RCTs, n=456)		RD 0.03 (95%CI -0.01 to 0.07)	RD -0.01 (95%CI -0.18 to -0.03) NNT 10	RD -0.11 (95%CI -0.05 to 0.03) NNT 9	RD 0.01 (95%CI -0.03 to 0.04)
		HC x Ther (5 RCTs, n=554)		RD 0.07 (95%CI -0.14 to -0.01) NNT 14	RD 0.02 (95%CI -0.08 to 0.04)	RD -0.02 (95%CI -0.05 to 0.01)	RD 0 (95%CI -0.03 to 0.003)
Toka <i>et al</i> 2019 [16]	RCT	MHFSC (n=56) HC (n=56)	Ulcers	98.2% (55/56) 80.4% (45/56) P=0.004	3.6 % (2) 17.7 (8) P=0.04	—	—
Young-Seok <i>et al</i> 2008 [20]	RCT	HC (n=21) EBL (n=20)	Mallory-Weiss	100% (21/21) 100% (20/20) P=1.00	6% (1/21) 10% (2/20) P=0.61	0 0 P=1.00	0 0 P=1.00
Barakat <i>et al</i> 2018 [23]	Meta-analysis	5 RCT EBL (n=75) HC (n=87)	Dieulafoy's	0.96 (CI 0.88-0.99) 0.91 (CI 0.83-0.96) RR 1 (CI 0.96-1.05)	0.06 (CI 0.02-0.15) 0.17 (CI 0.10-0.28) RR 0.37 (CI 0.12-1.09)	—	—
Nagata <i>et al</i> 2018 [28]	Cohort	EBL (n=61) HC (n=47)	Diverticulum	98.4% (60/61) 100% (47/47) P=0.378	16.4 % (10/61) 38.3% (18/47) P=0.018	0 0 NA	1.6% (1/61) 4.25% (2/47) P=0.412
Schmidt <i>et al</i> 2018 [35]	RCT	HC (n=33) OTSC (n=33)	Ulcers	57.6% (19/33) 93.9% (31/33) P=0.001	57.6% (19/33) 15.2% (5/33) P=0.001	3% (1/33) 3% (1/33) P=0.999	6.3% (2/33) 12.1%(4/33) P=0.632

*Numbers in bold represent significant value

CI, confidence interval; EBL, endoscopic band ligation; HC, hemoclips; INJ, injection therapy; MHFSC, monopolar hemostatic forceps soft coagulation; NA, not applicable; OTSC, over-the-scope- clip; RCT, randomized controlled trial; RD, risk difference; RR, relative risk; Ther, thermocoagulation

non-clipping group, delayed bleeding occurred in 6 patients (13.6%, $P=0.053$) and delayed perforation occurred in 3 patients (6.8%, $P=0.350$). Therefore, prophylactic clipping showed a tendency towards lower complication rates [40]. In view of the above, for resected duodenal lesions >10 mm, the recommendation is to close the resection site using endoclips to prevent delayed bleeding and perforation [38-41]. Notably, RCTs are needed to assess whether systematic clipping prophylaxis reduces the incidence of late complications after endoscopic resection. Given the infrequency of duodenal lesions and the difficulty of endoscopic resection, there have been few large-scale studies to date.

Colon

Various polypectomy and mucosectomy techniques within the colon have been developed with advances in imaging

technology and devices [42]. As a result, adverse events, especially bleeding and perforation, have also increased in absolute numbers. A meta-analysis that included 6529 colonoscopies involving mucosectomies showed a delayed bleeding rate of 4% and a perforation rate of 1.1% [43]. Patient-related perforation risk factors include the presence of diverticulosis, inflammatory bowel disease and corticosteroid use. The endoscopist's experience and polyp morphology also influence the rate of adverse events. Risk factors described for bleeding after polypectomy include polyp size above 2 cm, right sided colonic polyps, intraprocedural bleeding, use of antithrombotic agents, and exposed vessels in the submucosa after resection [43,44]. The use of microprocessor-controlled electrocautery confers a lower risk of bleeding and perforation after polypectomy [45,46].

Endoclippping is not routinely indicated in the resection of colonic polyps <20 mm, because its use does not reduce the risk of postprocedural bleeding [42,47]. In an RCT

enrolling 1499 patients, prophylactic clipping was not necessary to prevent post-polypectomy delayed bleeding for polyps <2 cm [48]. In another study, 1098 patients who had polyps ≥ 10 mm were randomly divided into 2 groups (clipping or non-clipping groups). The authors found that placement of prophylactic endoclips did not affect the incidence of delayed post-polypectomy bleeding [49]. On the other hand, a recent multicenter RCT with 919 patients, which evaluated the influence of endoscopic clipping of post-polypectomy defects >20 mm, showed that clipping reduced the overall risk of delayed hemorrhage. This benefit was limited to lesions in the proximal colon, where the bleeding risk was significantly lower when clips were applied compared to the control group (3.3% compared to 9.9%; $P<0.001$) [50].

A recent meta-analysis of 9 RCTs (7197 colorectal lesions) assessed the efficacy of clipping in preventing bleeding after polypectomy. The results showed that the benefit of clipping in reducing bleeding was significant for large polyps (clipped vs. unclipped, odds ratio [OR] 0.54, 95%CI 0.30-0.97; $P=0.041$), and proximal lesions >20 mm (clipped vs. unclipped, OR 0.34, 95%CI 0.19-0.65; $P=0.021$). Thus if such lesions were not clipped, there would be 4-fold increase in the baseline risk of post-polypectomy bleeding [51]. According to 2 American guidelines, in non-pedunculated polyps >20 mm, whose Paris classification is of type 0-Is or type 0-II [52], the closure of the endoscopic resection area with clips decreases the incidence of late bleeding, especially in the right colon [42,43] (Fig. 1).

In pedunculated polyps (Paris classification Ip), prophylaxis for bleeding post-polypectomy with endoclips is recommended in those in which the polyp head is ≥ 20 mm, or if the pedicle is ≥ 10 mm [46,53]. The American Society for Gastrointestinal Endoscopy (ASGE) guidelines recommend the prophylactic application of endoclips for resection of polyps with a pedicle greater than 5 mm [40]. ESGE guidelines also suggest the use of a diluted epinephrine injection as an alternative or in association with mechanical hemostasis in the pretreatment of polyps with a large pedicle [46].

The SCALP (Study on Complications of Large Polypectomy) study, which evaluated 1504 patients, found that prophylactic endoscopic clipping was cost-effective for polyps >10 mm in patients on anticoagulant or antiplatelet therapy. Anticoagulant therapy was the risk factor most associated with delayed bleeding [53]. In the case of periprocedural bleeding or exposure of submucosal vessels, endoscopic coagulation (snare-tip soft coagulation or coagulation forceps) or mechanical therapy (clips or endoloop) is recommended, with or without the combined use of dilute adrenaline injection [46] (Fig. 2).

Signs predictive of perforation, such as the “target sign” (representing injury to the colon’s *muscularis propria* after mucosectomy and identified as a white to grey central circular disk on the transected surface of the specimen) should prompt consideration of endoscopic closure of the defect (Fig. 3).

Although the direct costs related to delayed bleeding are largely unreported, a Spanish prospective series of 1424

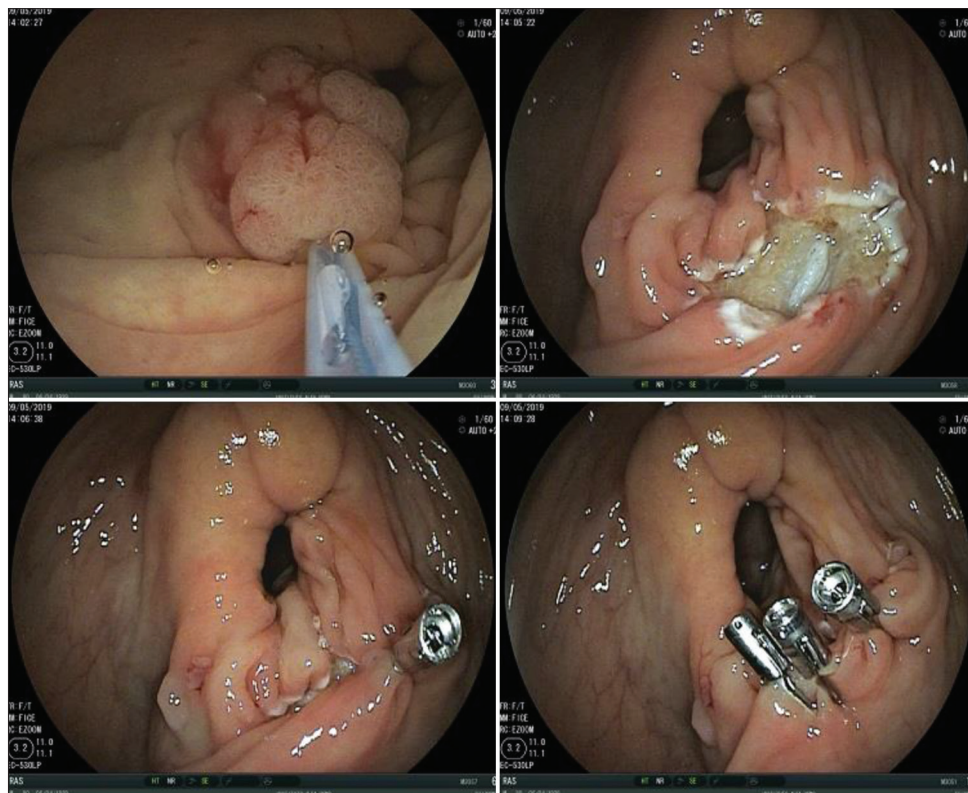


Figure 1 Underwater mucosectomy of a 22 mm lateral spreading tumor in right colon. Three hemoclips were positioned as post-polypectomy bleeding prophylaxis

endoscopic mucosal resections analyzed the cost-effectiveness of prophylactic clipping of large colorectal lesions (≥ 2 cm). In this study, bleeding costs were higher in relation to the prophylactic strategy in average and high-risk settings (age ≥ 75 years, American Society of Anesthesiologists classification III-IV, lesion size ≥ 40 mm, aspirin use, location of the lesion proximal to transverse colon) [54]. A recent publication evaluated the economic impact of prophylactic endoscopic clipping on large colonic polyps. It suggested that prophylactic clip closure after endoscopic resection of large colonic polyps, particularly those within the right colon, is cost-effective, but only if the clip device costs under \$100.00 (USD) [55].

Concluding remarks

The endoclip is an essential tool in modern endoscopic therapy. Its practicality, efficacy and safety are well established. Although thermal hemostasis has similar efficacy in the management of gastrointestinal bleeding, the mechanical compression exerted by clipping causes less tissue damage and also provides an anatomical marker. Endoscopic clipping is an alternative with lower morbidity than surgery for treatment of gastrointestinal bleeding. The prophylactic role of clipping is controversial, in spite of its widespread use, because of the significant costs involved with this practice. A prophylactic

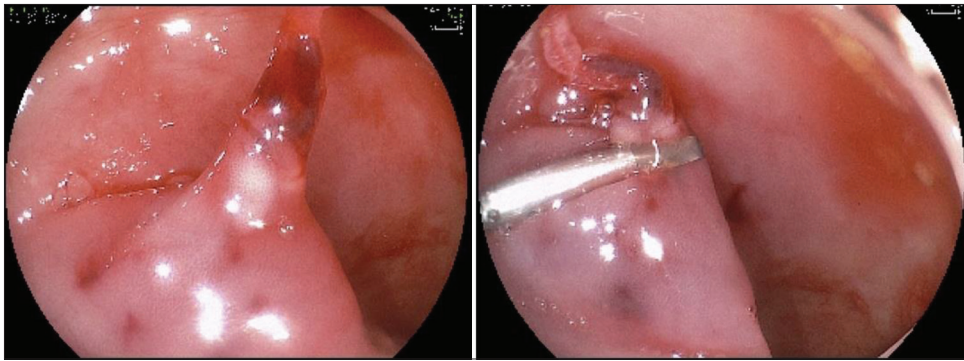


Figure 2 Polypectomy of a pedunculated polyp with bleeding during the procedure and an exposed vessel. Diluted epinephrine injection (1:10000) and endoscopic clipping were performed

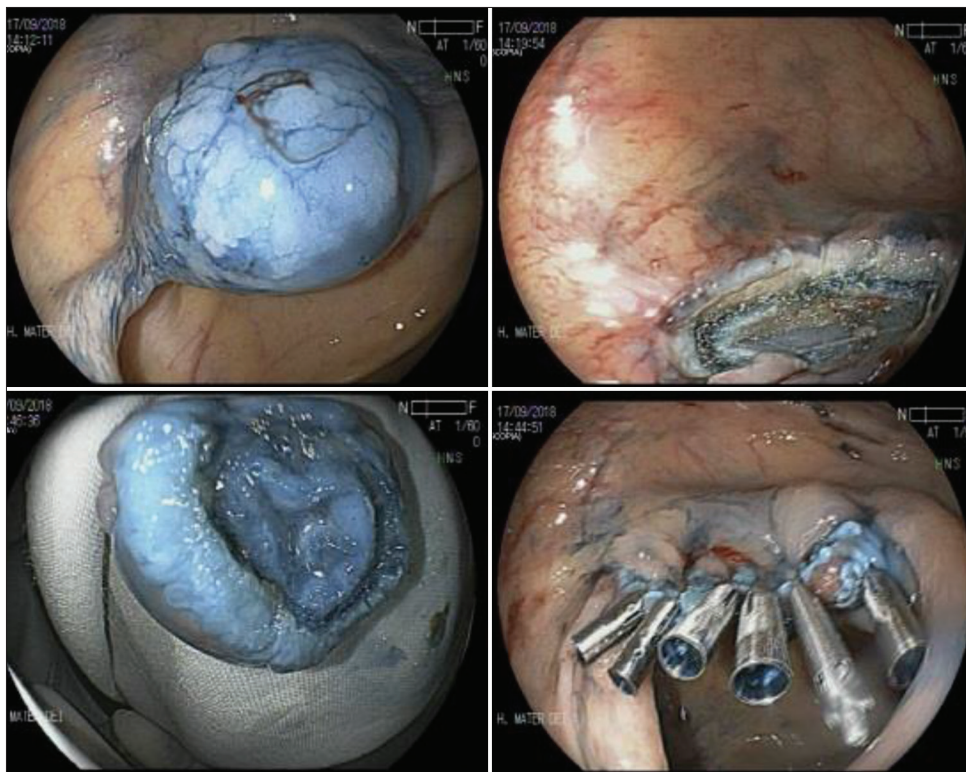


Figure 3 “Target sign” in a resected specimen of colonic mucosectomy represents a predictive sign of perforation. Closure of the defect was achieved with 6 metal clips

clipping strategy after endoscopic resection is not cost-effective for all lesions.

This review explored the accepted indications for prophylactic clipping in endoscopic resection. In general, it is indicated for pedunculated colonic polyps with a head ≥ 20 mm and pedicle ≥ 10 mm, as well as in non-pedunculated lesions ≥ 20 mm located in the proximal colon. Furthermore, in patients on anticoagulants or antiplatelet therapy, prophylactic closure of resection defects should be strongly considered. This practice significantly reduces the risk of delayed bleeding. Future studies are necessary to assess the use of preventative endoclipping in other segments of the digestive tract.

References

- Hayashi I, Yonezawa TM, Kuwabara T, Kudoh I. The study on stanch clips for the treatment by endoscopy. *Gastroenterol Endosc* 1975;17:92-101.
- Lin HJ, Hsieh YH, Tseng GY, Perng CL, Chang FY, Lee SD. A prospective, randomized trial of endoscopic hemoclip versus heater probe thermocoagulation for peptic ulcer bleeding. *Am J Gastroenterol* 2002;97:2250-2254.
- Shin EJ, Ko CW, Magno P, et al. Comparative study of endoscopic clips: duration of attachment at the site of clip application. *Gastrointest Endosc* 2007;66:757-761.
- Jensen DM, Machicado GA, Hirabayashi K. Randomized controlled study of 3 different types of hemoclips for hemostasis of bleeding canine acute gastric ulcers. *Gastrointest Endosc* 2006;64:768-773.
- Grupka MJ, Benson J. Endoscopic clipping. *J Dig Dis* 2008;9:72-78.
- Naseer M, Lambert K, Hamed A, Ali E. Endoscopic advances in the management of non-variceal upper gastrointestinal bleeding: A review. *World J Gastrointest Endosc* 2020;12:1-16.
- Kobara H, Mori H, Nishiyama N, et al. Over-the-scope clip system: A review of 1517 cases over 9 years. *J Gastroenterol Hepatol* 2019;34:22-30.
- Boonpongmanee S, Fleischer DE, Pezzullo JC, et al. The frequency of peptic ulcer as a cause of upper-GI bleeding is exaggerated. *Gastrointest Endosc* 2004;59:788-794.
- Hwang JH, Fisher DA, Ben-Menachem T, et al; Standards of Practice Committee of the American Society for Gastrointestinal Endoscopy. The role of endoscopy in the management of acute non-variceal upper GI bleeding. *Gastrointest Endosc* 2012;75:1132-1138.
- Karstensen JG, Ebigbo A, Aabakken L, et al. Nonvariceal upper gastrointestinal hemorrhage: European Society of Gastrointestinal Endoscopy (ESGE) Cascade Guideline. *Endosc Int Open* 2018;6:E1256-E1263.
- Lau JYW, Yu Y, Tang RSY, et al. Timing of endoscopy for acute upper gastrointestinal bleeding. *N Engl J Med* 2020;382:1299-1308.
- Gralnek IM, Dumonceau JM, Kuipers EJ, et al. Diagnosis and management of nonvariceal upper gastrointestinal hemorrhage: European Society of Gastrointestinal Endoscopy (ESGE) Guideline. *Endoscopy* 2015;47:a1-a46.
- Saltzman JR, Strate LL, Di Sena V, et al. Prospective trial of endoscopic clips versus combination therapy in upper GI bleeding (PROTECCT—UGI bleeding). *Am J Gastroenterol* 2005;100:1503-1508.
- Sung JJ, Tsoi KK, Lai LH, Wu JC, Lau JY. Endoscopic clipping versus injection and thermo-coagulation in the treatment of non-variceal upper gastrointestinal bleeding: a meta-analysis. *Gut* 2007;56:1364-1373.
- Barakat F, Moura E, Bernardo W, et al. Endoscopic hemostasis for peptic ulcer bleeding: systematic review and meta-analyses of randomized controlled trials. *Surg Endosc* 2016;30:2155-2168.
- Toka B, Eminler AT, Karacaer C, Uslan MI, Koksas AS, Parlak E. Comparison of monopolar hemostatic forceps with soft coagulation versus hemoclip for peptic ulcer bleeding: a randomized trial (with video). *Gastrointest Endosc* 2019;89:792-802.
- Bharucha AE, Gostout CJ, Balm RK. Clinical and endoscopic risk factors in the Mallory-Weiss syndrome. *Am J Gastroenterol* 1997;92:805-808.
- Lee S, Ahn JY, Jung HY, et al. Effective endoscopic treatment of Mallory-Weiss syndrome using Glasgow-Blatchford score and Forrest classification. *J Dig Dis* 2016;17:676-684.
- Huang SP, Wang HP, Lee YC, et al. Endoscopic hemoclip placement and epinephrine injection for Mallory-Weiss syndrome with active bleeding. *Gastrointest Endosc* 2002;55:842-846.
- Cho YS, Chae HS, Kim HK, et al. Endoscopic band ligation and endoscopic hemoclip placement for patients with Mallory-Weiss syndrome and active bleeding. *World J Gastroenterol* 2008;14:2080-2084.
- Cipolletta L, Cipolletta F, Marmo C, et al. Mechanical methods to endoscopically treat nonvariceal upper gastrointestinal bleeding: review of the technique, indications and efficacy of mechanical methods including clips, OTSC and bands, to control upper GI bleeding. *Tech Gastrointest Endosc* 2016;18:191-197.
- Park CH, Sohn YH, Lee WS, et al. The usefulness of endoscopic hemoclip for bleeding Dieulafoy lesions. *Endoscopy* 2003;35:388-392.
- Barakat M, Hamed A, Shady A, Homsy M, Eskaros S. Endoscopic band ligation versus endoscopic hemoclip placement for Dieulafoy's lesion: a meta-analysis. *Eur J Gastroenterol Hepatol* 2018;30:995-996.
- Nagata N, Ishii N, Manabe N, et al. Guidelines for Colonic Diverticular Bleeding and Colonic Diverticulitis: Japan Gastroenterological Association. *Digestion* 2019;99(Suppl 1):1-26.
- Jensen DM, Ohning GV, Kovacs TO, et al. Natural history of definitive diverticular hemorrhage based on stigmata of recent hemorrhage and colonoscopic Doppler blood flow monitoring for risk stratification and definitive hemostasis. *Gastrointest Endosc* 2016;83:416-423.
- Simpson PW, Nguyen MH, Lim JK, Soetikno RM. Use of endoclips in the treatment of massive colonic diverticular bleeding. *Gastrointest Endosc* 2004;59:433-437.
- Kishino T, Kanemasa K, Kitamura Y, Fukumoto K, Okamoto N, Shimokobe H. Usefulness of direct clipping for the bleeding source of colonic diverticular hemorrhage (with videos). *Endosc Int Open* 2020;8:E377-E385.
- Nagata N, Ishii N, Kaise M, et al. Long-term recurrent bleeding risk after endoscopic therapy for definitive colonic diverticular bleeding: band ligation versus clipping. *Gastrointest Endosc* 2018;88:841-853.
- Manta R, Galloro G, Mangiavillano B, et al. Over-the-scope clip (OTSC) represents an effective endoscopic treatment for acute GI bleeding after failure of conventional techniques. *Surg Endosc* 2013;27:3162-3164.
- Kirschniak A, Traub F, Kueper MA, Stüker D, Königsrainer A, Kratt T. Endoscopic treatment of gastric perforation caused by acute necrotizing pancreatitis using over-the-scope clips: a case report. *Endoscopy* 2007;39:1100-1102.
- Wong Kee Song LM, Banerjee S, Barth BA, et al; ASGE Technology Committee. Emerging technologies for endoscopic hemostasis. *Gastrointest Endosc* 2012;75:933-937.
- Voermans RP, Le Moine O, von Renteln D, et al. Efficacy of endoscopic closure of acute perforations of the gastrointestinal tract. *Clin Gastroenterol Hepatol* 2012;10:603-608.
- Baron TH, Song LM, Ross A, Tokar JL, Irani S, Kozarek RA. Use of an over-the-scope clipping device: multicenter retrospective results

- of the first U.S. experience (with videos). *Gastrointest Endosc* 2012;**76**:202-208.
34. Honegger C, Valli PV, Wiegand N, Bauerfeind P, Gubler C. Establishment of over-the-scope-clips (OTSC®) in daily endoscopic routine. *United European Gastroenterol J* 2017;**5**:247-254.
 35. Schmidt A, Gölder S, Goetz M, et al. Over-the-scope clips are more effective than standard endoscopic therapy for patients with recurrent bleeding of peptic ulcers. *Gastroenterology* 2018;**155**:674-686.
 36. Dominguez VM, Santander ADMC, García-Buey LC. Portal hypertensive polyps, a new entity? *Rev Esp Enferm Dig* 2016;**108**:279-280.
 37. Gaspar JP, Stelow EB, Wang AY. Approach to the endoscopic resection of duodenal lesions. *World J Gastroenterol* 2016;**22**:600-617.
 38. Hara Y, Goda K, Dobashi A, et al. Short- and long-term outcomes of endoscopically treated superficial non-ampullary duodenal epithelial tumors. *World J Gastroenterol* 2019;**25**:707-718.
 39. Iizuka T, Kikuchi D, Hoteya S, et al. How to manage duodenal tumors with EMR or ESD. *Gastroenterol Endosc* 2011;**53**:87-94.
 40. An JY, Kim BW, Park JM, Kim TH, Lee J. Prophylactic clipping for the prevention of delayed complication after endoscopic resection for superficial non-ampullary duodenal tumor. *Endoscopy* 2019;**51**:S118.
 41. Yamamoto Y, Yoshizawa N, Tomida H, Fujisaki J, Igarashi M. Therapeutic outcomes of endoscopic resection for superficial non-ampullary duodenal tumor. *Dig Endosc* 2014;**26**(Suppl 2):50-56.
 42. Kaltenbach T, Anderson JC, Burke CA, et al. Endoscopic removal of colorectal lesions-recommendations by the US multi-society task force on colorectal cancer. *Gastrointest Endosc* 2020;**91**:486-519.
 43. Kothari ST, Huang RJ, Shaikat A, et al; ASGE Standards of Practice Committee Chair. ASGE review of adverse events in colonoscopy. *Gastrointest Endosc* 2019;**90**:863-876.
 44. Reumkens A, Rondagh EJ, Bakker CM, Winkens B, Masclee AA, Sanduleanu S. Post-colonoscopy complications: a systematic review, time trends, and meta-analysis of population-based studies. *Am J Gastroenterol* 2016;**111**:1092-1101.
 45. Kishihara T, Chino A, Uragami N, et al. Usefulness of sodium hyaluronate solution in colorectal endoscopic mucosal resection. *Dig Endosc* 2012;**24**:348-352.
 46. Ferlitsch M, Moss A, Hassan C, et al. Colorectal polypectomy and endoscopic mucosal resection (EMR): European Society of Gastrointestinal Endoscopy (ESGE) Clinical Guideline. *Endoscopy* 2017;**49**:270-297.
 47. Boumitri C, Mir FA, Ashraf I, et al. Prophylactic clipping and post-polypectomy bleeding: a meta-analysis and systematic review. *Ann Gastroenterol* 2016;**29**:502-508.
 48. Matsumoto M, Kato M, Oba K, et al. Multicenter randomized controlled study to assess the effect of prophylactic clipping on post-polypectomy delayed bleeding. *Dig Endosc* 2016;**28**:570-576.
 49. Feagins LA, Smith AD, Kim D, et al. Efficacy of prophylactic hemoclips in prevention of delayed post-polypectomy bleeding in patients with large colonic polyps. *Gastroenterology* 2019;**157**:967-976.
 50. Pohl H, Grimm IS, Moyer MT, et al. Clip closure prevents bleeding after endoscopic resection of large colon polyps in a randomized trial. *Gastroenterology* 2019;**157**:977-984.
 51. Spadaccini M, Albéniz E, Pohl H, et al. Prophylactic clipping after colorectal endoscopic resection prevents bleeding of large, proximal polyps: meta-analysis of randomized trials. *Gastroenterology* 2020 Apr 1 [Online ahead of print]. doi: 10.1053/j.gastro.2020.03.051
 52. The Paris endoscopic classification of superficial neoplastic lesions: esophagus, stomach, and colon: November 30 to December 1, 2002. *Gastrointest Endosc* 2003;**58**:S3-S43.
 53. Amato A, Radaelli F, Correale L, et al; Bowell Group. Intra-procedural and delayed bleeding after resection of large colorectal lesions: The SCALP study. *United European Gastroenterol J* 2019;**7**:1361-1372.
 54. Albeniz E, Gonzalez MF, Martínez-Ares D, et al. Cost-effectiveness of prophylactic clipping after colorectal endoscopic mucosal resection and economic impact according to a bleeding risk score. *Gastrointest Endosc* 2016;**83**:377-378.
 55. Shah ED, Pohl H, Rex DK, et al. Valuing innovative endoscopic techniques: prophylactic clip closure after endoscopic resection of large colon polyps. *Gastrointest Endosc* 2020;**91**:1353-1360.