

Management of complex perianal Crohn's disease

Lara Aguilera-Castro, Carlos Ferre-Aracil, Ana Garcia-Garcia-de-Paredes, Enrique Rodriguez-de-Santiago, Antonio Lopez-Sanroman

University Hospital Ramón y Cajal (Affiliated to Universidad de Alcalá), Madrid, Spain

Abstract

Patients with Crohn's disease often develop perianal disease, successfully managed in most cases. However, its most aggressive form, complex perianal disease, is associated with high morbidity and a significant impairment in patients' quality of life. The aim of this review is to provide an updated approach to this condition, reviewing aspects of its epidemiology, diagnosis and therapeutic alternatives. Emerging treatment options are also discussed. A multidisciplinary assessment of these patients with a coordinated medical and surgical approach is crucial.

Keywords Crohn's disease, perianal disease, perianal fistula, perianal abscess

Ann Gastroenterol 2017; 30 (1): 1-12

Introduction

Crohn's disease (CD) is a chronic inflammatory condition, probably arising from an altered interaction between the host and environmental factors. Therapy for CD has seen significant developments during the last years. We have witnessed the arrival of biological therapies, the rationalizing of immunosuppression, an effective prevention of many adverse events, and the design of better surgical techniques, among others. However, CD still sometimes surprises patients and clinicians, ruthlessly affecting personal quality of life (QoL). One of the best examples of this aggressive behavior is perianal CD (PCD). Affected individuals will not only suffer from painful short-term lesions, but can also have their QoL diminished, and even their social performance may be influenced negatively in the long run.

In this review, we have tried to provide an overview of the current aspects regarding what has been designated complex PCD (CPCD). This review will focus on perianal fistulas, its most characteristic manifestation. We hope to contribute to a better understanding of this peculiar manifestation of CD.

Gastroenterology and Hepatology Department, University Hospital Ramón y Cajal (affiliated with Universidad de Alcalá), Madrid, Spain

Conflict of Interest: None

Correspondence to: Antonio Lopez-Sanroman, Gastroenterology and Hepatology Department, University Hospital Ramon y Cajal, 28034 Madrid, Spain, e-mail: alsanroman@salud.madrid.org

Received 20 March 2016; accepted 21 September 2016; published online 27 October 2016

DOI: <https://doi.org/10.20524/aog.2016.0099>

Definition, epidemiology and burden of CPCD

Many patients with CD live with a considerable symptom burden despite new and better medical treatments [1]. Whenever CD affects the perianal area, it does so mainly in the form of fistulas and abscesses. The prevalence of PCD in different studies varies between 21% and 54% of CD patients; it is more frequent in cases of isolated colonic involvement (up to 41%), versus only 12% in patients with isolated ileal disease. It has been identified as an indicator of poor prognosis and is associated with increased healthcare costs [2,3].

PCD is not a homogeneous condition. Some cases can be managed with simple medical or surgical gestures, and have no influence on the overall disease burden. However, others will require a much more aggressive approach to control the disease. There is no clear definition of CPCD, even in the latest clinical guidelines from the European Crohn's and Colitis Organization (ECCO) on the management of CD [3]. For the purpose of this review, CPCD can be defined following the criteria proposed by Sandborn [4]: "A complex fistula is high (a high fistula involves more than 2/3 of the external sphincter, high intersphincteric or high transsphincteric or extrasphincteric or suprasphincteric origin of the fistula tract), may have multiple external openings, may be associated with the presence of a perianal abscess, may be associated with the presence of a rectovaginal fistula, may be associated with the presence of an anorectal stricture, and may be associated with the presence of active rectal disease at endoscopy".

Complex perianal fistulas are more difficult to treat than simple fistulas, and therapy discontinuation results in a high rate of recurrence, as shown in a St Mark's Hospital study in the pre-biologic era (1994) [5]. In this study, 87 patients with fistulizing CD were followed during 6 years from presentation. Among these, 65% had perianal fistulas, 80% of which were classified as complex. During follow up, 14% of patients failed

to show fistula healing, and half of patients with complex fistulas eventually required a stoma, or a resection, including proctectomy. Perianal and recto-vaginal fistulas took a median of 2.6 years to heal. Another large retrospective cohort addressing the natural history of CPCD (also mainly set in the pre-biologic era, 1980 to 2000) was conducted by Molendijk *et al*, at Erasmus Medical Centre in Rotterdam, The Netherlands [6]. They collected data from 232 patients with a median follow up of 10 years. In their experience, 78% of patients with PCD developed complex fistulas at some time. Simple fistulas healed more often than complex fistulas (88.2% vs. 64.6%), and the recurrence rate was higher in complex fistulas (41.9% vs. 26.7%). Regarding surgical outcomes, patients with complex fistulas were more likely to receive permanent fecal diversion (63.8% vs. 26.7%) and rectum amputation (25.5% vs. 6.7%). The authors concluded that, after protracted follow up, only one third of patients with CPCD achieved durable remission by conventional treatment strategies.

It is important to highlight that CPCD results in increased healthcare resource use and high costs. A recent Spanish retrospective multicenter study of 97 cases of CPCD, conducted in the Madrid area [2], analyzed baseline patient characteristics and treatments indicated in real-life clinical practice. Antibiotics were administered in 32.3% of cases, immunomodulators in 20.5%, biological agents in 20.3%, and 27% were treated surgically. The mean annual global cost per patient was €8,289. Of this expense, 75% was due to the use of pharmacological treatments (mainly biological agents); 12.4% was accounted for by hospitalizations and surgery and 7.7% by outpatient medical visits. Previous studies that addressed the direct costs of CD in the same area, pointed towards an average of €2,104-4,464 per patient/year (reaching €10,594 per patient/year if biologics were prescribed) [7]. Thus, the authors concluded that a relatively small percentage of patients with CD (those with fistulas and CPCD) account for a large part of the overall burden and economic cost associated with the disease. Moreover, indirect costs, derived from work absenteeism and sick leave, are seldom contemplated in this type of study, but should definitely be included in the global burden of CPCD.

PCD and CPCD result in a high morbidity among young individuals; about 25% of patients with CD present during their childhood or adolescence, and it is estimated that one out of every three pediatric patients will develop perianal lesions. Zwintscher *et al* conducted a retrospective study to address the impact of PCD in this young population [8]. They studied a large cohort of patients diagnosed with pediatric inflammatory bowel disease (IBD), 63% of whom had CD. PCD was present in 4.1% of patients and 19.17% of those had complex fistulas. Pediatric patients with perianal disease were twice as likely to need surgery. In addition, they spent on average 1.3 additional days in hospital admissions, which cost US\$5,838 more when compared with hospitalizations in those without PCD.

As mentioned before, one common outcome in patients with CPCD is the need for surgery in cases refractory to medical therapy. There are very few studies that assess QoL after surgery for perianal fistulizing CD. Riss *et al* conducted a study in Vienna to assess QoL and sexual function in these patients [9]. They followed 88 consecutive cases operated for

PCD (patients with a previous stoma were excluded from the analysis). Patients completed a self-administered questionnaire, including the International Index of Erectile Function (IIEF), Female Sexual Function Index (FSFI), Short Form-12 Health Survey (SF-12), and the IBD Questionnaire (IBDQ). They were matched by age and sex with healthy controls. Patients presented worse scores on the SF-12 (including physical and mental health) and IBDQ, showing an impaired QoL compared with healthy controls. However, there were surprisingly no significant differences between the two groups in any domain of the sexual function questionnaires (IIEF and FSFI).

In conclusion, CPCD is not rare among patients with CD. It results in higher morbidity, a significant impairment in QoL in both adult and young patients, and higher costs.

Classification and diagnosis of CPCD

Typical symptoms of perianal fistulas are anal pain with defecation, perianal itching, bleeding, and discharge of pus. They should also be expected to appear in patients with a previously drained abscess. The differential diagnosis for fistulizing perianal CD includes traumatic lesions, hidradenitis suppurativa, tuberculosis, HIV infection, lymphogranuloma venereum, perianal actinomycosis, and post-rectal dermoid inclusion cyst, among others. Anal abscesses, in turn, may present with pain in the anal area, associated with fever in severe cases. They can be suspected during physical examination by observing perianal swelling, erythema, induration and fluctuation, but are sometimes less symptomatic, so that physical examination alone is insufficient to rule them out.

Classification of perianal fistulas in CD is important in order to determine an optimal management strategy. Several approaches have been proposed, among which Park's classification achieves the best anatomic precision. It describes five different types of fistula: superficial, intersphincteric, transsphincteric, suprasphincteric and extrasphincteric [10]. A simple system has been devised by the American Gastroenterological Association (AGA), in which fistulas are divided into simple and complex [4]. Simple fistulas are low fistulas that involve superficial tissue, and include subcutaneous and intersphincteric and intrasphincteric fistulas that remain below the dentate line, have a single opening and are not associated with perianal complications. In contrast, complex fistulas, i.e., high intersphincteric, high transsphincteric, suprasphincteric and extrasphincteric, may have multiple openings and may be associated with an abscess, proctitis, rectal stricture or connection with bladder or vagina. All types of anterior fistulas in women are generally considered complex, because of the potential genital complications.

Imaging is crucial to assess fistula anatomy, to rule out septic complications such as an abscess, to plan treatment and to monitor the therapeutic response. Pelvic magnetic resonance imaging (MRI) should be considered in all complex fistulas (Fig. 1). It offers a high accuracy in differentiating active granulation and fibrotic tissues, and precision in diagnosing septic fistula complications. Moreover, it is a noninvasive and

radiation-free procedure. The diagnostic specificity of MRI ranges from 76-100% [11]. Its widespread use is only limited by access and cost.

Endoanal ultrasound (EUS) is a reliable alternative to MRI for diagnosing perianal fistulas. It can obtain 2D or 3D images, and local infusion of hydrogen peroxide may improve visualization [12]. Its main limitations are endoscopist expertise, the presence of rectal stenosis, and its low accuracy in visualizing higher regions such as the ischioanal fossa. According to some authors, high-resolution 3D EUS could detect the so-called "Crohn's ultrasound fistula sign", characterized by a hypoechogenic fistula tract surrounded by a well-defined hyperechogenic area with a thin hypoechogenic edge. This sign may discriminate Crohn's fistulas from other types of fistulas [13], although this has not been substantiated in controlled studies.

A meta-analysis comparing MRI and EUS for perianal fistula assessment [14] (Table 1) included four studies and found comparable sensitivities for MRI [0.87, 95% confidence interval (CI) 0.63-0.96] and EUS (0.87, 95% CI 0.70-0.95), although the specificity for MRI (0.69, 95% CI 0.51-0.82) was higher than that for EUS (0.43, 95% CI 0.21-0.69). Transperineal ultrasound may represent another method for detecting perianal complications in CD. There are several studies that report a high sensitivity (up to 85%) for the diagnosis of perianal and recto-vaginal fistulas [15].

Examination under anesthesia (EUA) is considered by ECCO guidelines as the gold standard when performed by an experienced colorectal surgeon. It has an accuracy of 90% for establishing the diagnosis of perianal disease [16]. This procedure allows immediate therapeutic intervention such as drain abscesses, seton placement or fistulotomy. If an abscess is suspected, EUA should not be delayed (Fig. 2).

Several studies have compared the suitability of MRI, EUS and EUA for CPCD diagnosis. In a prospective study of 32 patients, accuracies of 87%, 91% and 91%, respectively, were reported [16]. The combination of EUA with either MRI or EUS improved the accuracy of the initial assessment to reach

100% [16]. Another study found that MRI was more sensitive (0.97, 95% CI 0.92-1.01) than clinical examination (0.75, 95% CI 0.65-0.86) but comparable to EUS (0.92, 95% CI 0.85-0.99) in differentiating complex from simple disease [17].

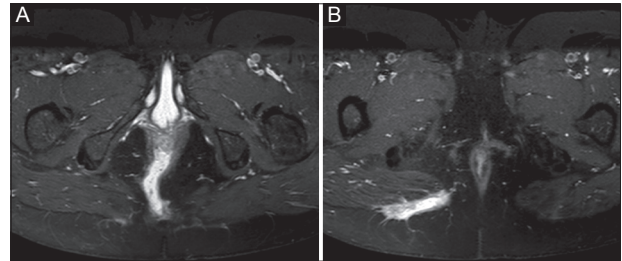


Figure 1 Transsphincteric fistula. Axial T1-weighted image (A) demonstrated high signal intensity tract (13 cm in length) under puborectalis muscle. Axial T-weighted image (B) in the same patient illustrates the progression fistula to the gluteal cleft

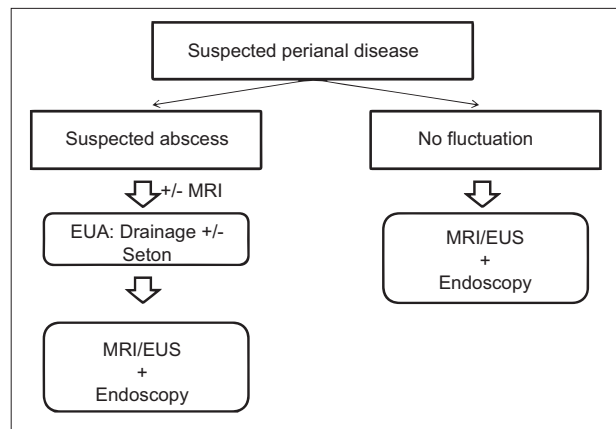


Figure 2 Diagnostic algorithm for complex perianal Crohn's disease. If abscess is suspected, MRI may be used as a diagnostic method, if readily available, before drainage [18] MRI, magnetic resonance imaging; EUS, endoanal ultrasound; EUA, examination under anesthesia

Table 1 MRI, EUS, transperineal ultrasound and EUA trials for fistulizing Crohn's disease

Authors and study design	Group 1	Group 2	Results
Siddiqui <i>et al</i> [14] Meta-analysis: four randomized trials (n=481)	MRI	EUS	MRI: Sensitivity 0.87 (95% CI 0.63-0.96) and specificity 0.69 (95% CI 0.51-0.82) in detecting fistulas EUS: Sensitivity 0.87 (95% CI 0.70-0.95) and specificity 0.43 (95% CI 0.21-0.69) in detecting fistulas
Maconi <i>et al</i> [15] Prospective, blind-comparison (n=46)	Transperineal ultrasound in the detection of perianal and recto-vaginal fistulas compared with results of EUS	No comparison arm	Transperineal ultrasound: Sensitivity 84.9%
Schwartz <i>et al</i> [16] Prospective, blind-comparison (n=34)	MRI, EUS and EUA		Accuracy MRI 87% (95% CI 69-96%), EUS 91% (95% CI 75-98%) and EUA 91% (95% CI 75-98%)
Sahni <i>et al</i> [17] Systematic review: 2 studies (n=156)	MRI	EUS	MRI: Sensitivity 0.97 (95% CI 0.92-1.01) and specificity 0.96 (95% CI 0.90-1.02) EUS: Sensitivity 0.92 (95% CI 0.85-0.99) and specificity 0.85 (95% CI 0.75-0.95)

MRI, magnetic resonance imaging; EUS, endoanal ultrasound; EUA, examination under anesthesia; 95% CI, 95% confidence interval

Fistulography and CT should not be routinely used for the diagnosis and classification of CPCD. Their main limitations are the use of ionizing radiations and the poor resolution in differentiating fistulas and pelvic floor muscles [18]. Additionally, fistulography is not devoid of complications.

Proctosigmoidoscopy should be performed in all patients with CPCD, in order to determine the extent and severity of inflammation, and to rule out complications such as strictures and cancer [18]. The presence of proctitis has consistently been associated with non-healing of fistula tracts and with a higher proctectomy rate [5].

Different methods and indexes have been proposed to clinically measure the activity of fistulas. The perianal disease activity index (PDAI) score includes the evaluation of 5 elements: fistula discharge, pain and restriction of activities, sexual activity restriction, type of perianal disease, and degree of induration (Table 2) [19]. A PDAI score >4 suggests active fistula drainage or local inflammation, with an accuracy of 87% [20]. This score has been validated in several clinical trials [21]. A simple way to evaluate fistula activity is the so-called “fistula drainage assessment” based on the examiner’s perception. It classifies fistulas as “open” if pus discharge is observed after digital compression. Clinical improvement or response is achieved if there is a reduction of 50% or more in the number of draining fistulas in two consecutive visits, and remission is established when draining fistulas are absent in two consecutive visits.

External openings sometimes heal while inflammatory changes persist in the fistula tracts. For this reason, the use of MRI or EUS to monitor the evolution of CPCD after medical and surgical therapy is generally recommended. In 2003, van Assche proposed an MRI-based score, clinically validated but showing a poor correlation with PDAI [22].

Treatment of CPCD

It is important to stress a few points when approaching a patient with PCD:

- a) PCD is very frequent and its symptoms can be disproportionately mild relative to its anatomic aggressiveness. Therefore, a thorough clinical examination of the perianal region has to be performed at the first contact with a patient who has suspected or known CD, and should be repeated from time to time, especially if new symptoms develop.
- b) The diagnosis of PCD has to be followed first by an immediate damage control policy. This involves the treatment of local infection, which is always a factor that contributes to patients’ discomfort and anal sphincter destruction. Antibiotics are generally prescribed at this stage, usually a combination of ciprofloxacin and metronidazole. Amoxicillin-clavulanate, or even parenteral imipenem or piperacillin-tazobactam may be preferred if the septic component is predominant (“pelvic sepsis”).
- c) Drainage of a perianal abscess, if present, is essential to control local infection.
- d) Steroids do not play a role in managing PCD and must be actively avoided.

Table 2 Perianal disease activity index [19]

Item	Points
Discharge	
No discharge	0
Minimal mucous discharge	1
Moderate mucous or purulent discharge	2
Substantial discharge	3
Gross fecal soiling	4
Pain/restriction of activities	
No activity restriction	0
Mild discomfort, no restriction	1
Moderate discomfort, some limitation	2
Marked discomfort, marked limitation	3
Severe pain, severe limitation	4
Restriction of sexual activity	
No restriction of sexual activity	0
Slight restriction of sexual activity	1
Moderate limitation of sexual activity	2
Marked limitation of sexual activity	3
Unable to engage in sexual activity	4
Type of perianal disease	
No perianal disease	0
Anal fissure or mucosal tear	1
<3 perianal fistulas	2
>3 perianal fistulas	3
Anal sphincter ulceration or fistulas with significant undermining skin	4
Degree of induration	
No induration	0
Minimal induration	1
Moderate induration	2
Substantial induration	3
Gross fluctuance/abscess	4

- e) A therapeutic plan has to be laid out, and it should involve a surgical consultation in almost all cases.
- f) As part of this therapeutic plan, a complete study should be ordered, including thiopurine methyltransferase assay, hepatitis B and C virus serologies, and diagnosis of latent tuberculosis according to local recommendations, among others.

Surgery

Although this is a gastroenterological review, it needs to be stressed that the management of CPCD is never complete without a surgical consultation. In more fortunate patients the

surgeon will just stand by. More frequently, surgery is needed to accomplish disease control. Perhaps more importantly, surgery can be the last and only resort in ultra-refractory patients.

Commonly, the surgeon's first participation is related to abscess drainage. In early stages, surgical gestures should be conservative in order to prevent the destruction of muscular tissue and to preserve anal function. Debris evacuation may be achieved by the insertion of simple drains in the presence of abscesses. The use of setons is generally avoided at this stage, and their placement can be performed more safely after the abscess has been evacuated and the anatomy of the fistula has been outlined with imaging techniques and endoscopy. It has to be emphasized that medical therapy attempted without a proper surgical counterpart will be less successful and sometimes risky.

The exact timing for seton placement and removal is a matter of ongoing controversy; in fact, ECCO guidelines do not specify a time interval. As mentioned above, setons are sometimes avoided in emergency surgery, and can be more safely placed once local sepsis has been controlled, by a more experienced surgeon, and after imaging techniques and endoscopy have outlined the anatomy of fistulous disease [23]. Setons can be left in place for as long as necessary, even for months, and the decision to extract them has to be taken individually during one of the several follow-up surgical visits that will generally be needed. A recent systematic review performed by Joline de Groof *et al* included 10 non-controlled studies, with a total of 305 patients treated with setons [24]. Complete fistula closure rate varied between 13.6-100% and recurrence ranged from 0-83%. Seton removal was always decided by the surgeon, and was performed between 3 weeks and 40 months following placement. Some recent studies suggest that seton removal after complete induction with anti-tumor necrosis factor (TNF)- α , or at least after the fifth dose of infliximab, may be beneficial in terms of a lower recurrence rate [25]. Any combination of seton placement, immunomodulators, and anti-TNF- α seems to achieve better results than seton placement alone [24].

EUA is the gold standard for identifying the disposition and anatomical relationships of fistulas, although it should be complemented by imaging techniques [16]. The importance of relying on an experienced surgeon cannot be underestimated. Perianal anatomy is not simple, and the temptation to do more than is strictly needed must be avoided. In a few cases, the complexity of the perianal disease is so high, and tissue destruction so significant, that a temporary ileostomy will be the best option for controlling structural damage and alleviating the patient's condition [26]. This will allow tissue healing, and transit may be reconstructed in the future.

During medical therapy, failure to respond to treatment or the onset of new symptoms may sometimes warrant a second EUA. This is very important if major changes in therapy are considered, such as progressing from immunomodulators to biological agents, or the use of advanced therapies.

Cases refractory to medical therapy may be managed surgically. This is clearly beyond the scope of this review, and the reader should look into recent and comprehensive papers [27]. Several techniques, such as advancement flap, laser therapy, and ligation of the intersphincteric fistula tract,

among others, can be attempted, but only by an experienced surgical team.

Definitive fecal diversion with colostomy or ileostomy is sometimes the only resort [26,28]. Careful consideration should be given on a case-by-case basis to the possibility of completing this by proctectomy. Persistence of rectal inflammation (sometimes manifested as peristomal pyoderma), the possibility of malignization and the maintenance of some fistulas by the presence of the rectal stump, all would argue in favor of proctectomy. The distinct possibility of adverse outcomes of proctectomy [29], such as erectile dysfunction in men, or the appearance of a persistent perineal sinus after rectal excision, should always be kept in mind.

Antibiotics

Other than for controlling perianal sepsis, as stated above, antibacterial agents are recommended in the treatment of perianal fistulas in CD. However there are discrepancies in their indications, and it is unclear whether they really represent a complete therapeutic alternative in the treatment of complex fistulas [30]. In our view, they should never be used alone. For complex fistulas, ECCO guidelines suggest that antibiotics should be used as the first line of therapy in combination with azathioprine or mercaptopurine [3]. Antibiotics are effective for improving symptoms; however, they do not usually induce complete healing.

Metronidazole and ciprofloxacin are the preferred agents. Usual doses include metronidazole 20 mg/kg/day, or 750-1000 mg/day divided into 3 or 4 doses, or ciprofloxacin 1000-1500 mg/day divided into 2 doses. There are no suggestions relative to treatment duration, but in most studies therapy lasts for 8-12 weeks. The drugs can also be used in combination.

Despite the recommendations, the efficacy of antibiotics alone for the treatment of PCD is based only on uncontrolled trials, case series, and one short good-quality trial. The latter was a randomized, double-blinded, placebo-controlled trial that included only 25 patients and compared ciprofloxacin, metronidazole and placebo for 10 weeks [31] (Table 3). Remission and response occurred more often in patients receiving ciprofloxacin, but the differences were not significant.

The use of antibiotics in association with immunomodulators or biologics has also been analyzed. In a prospective open-label trial, a combination of antibiotics (metronidazole or ciprofloxacin) and azathioprine was superior to antibiotics alone in achieving a response at week 20 [32]. A double-blind, placebo-controlled study of 24 patients showed that a combination of ciprofloxacin and infliximab (IFX) tended to be more effective than IFX alone [33]. The combination of antibiotics and adalimumab (ADA) has also been studied in a randomized, double-blind, placebo-controlled trial that included 76 patients. Clinical response was observed in 71% of patients treated with ADA plus ciprofloxacin and in 47% treated with ADA plus placebo ($P=0.047$). However, at week 24 no difference was observed in the clinical response between the two groups [34].

Table 3 Antibiotic trials for fistulizing Crohn's disease

Authors and study design	Group 1	Group 2	Results
Thia <i>et al</i> [31] Multicenter, prospective, double-blind, placebo-controlled study (n=25)	Ciprofloxacin (500 mg b.i.d.) or metronidazole (500 mg b.i.d.) for 10 weeks	Placebo for 10 weeks	Ciprofloxacin 40% response vs. metronidazole 14.3% vs. placebo 12.5% (P=0.43)
Dejaco <i>et al</i> [32] Prospective, open-label study (n=52)	Ciprofloxacin (500-1000 mg/day) and/or metronidazole (1000-1500 mg/day) for 8 weeks	Ciprofloxacin (500-1000 mg/day) and/or metronidazole (1000-1500 mg/day) for 8 weeks, plus azathioprine (2-2.5 mg/kg) from 0 or 8 week	Azathioprine group 48% response vs. no azathioprine group 15% (P=0.03)
West <i>et al</i> [33] Prospective, doubled-blind, placebo-controlled study (n=24)	Ciprofloxacin (1000 mg/day) for 12 weeks plus infliximab 5 mg/kg at weeks 6, 8 and 12	Placebo for 12 weeks plus infliximab 5 mg/kg at weeks 6, 8 and 12	Ciprofloxacin group 73% response vs. placebo group 39% (P=0.12)
Dewint <i>et al</i> [34] Prospective, doubled-blind, placebo-controlled study (n=76)	Ciprofloxacin (500 mg b.i.d.) for 12 weeks plus adalimumab (160/80 mg week 0, 2 and 40 mg every other week) for 24 weeks	Placebo for 12 weeks plus adalimumab (160/80 mg week 0, 2 and 40 mg every other week) for 24 weeks	Ciprofloxacin group 71% response vs. placebo group 47% (P=0.047)
Maeda <i>et al</i> [35] Prospective, doubled-blind, placebo-controlled study (n=74)	Metronidazole 10% ointment t.i.d. for 4 weeks	Placebo ointment for 4 weeks	Reduction in PDAI score of at least 5 points in metronidazole group 10 of 27 vs. placebo group 4 of 34 (P=0.031)

PDAI, perianal Crohn's disease activity index

Topical antibiotics were studied in a blinded, randomized, placebo-controlled study of 74 patients that compared 10% metronidazole ointment versus placebo during 4 weeks. Metronidazole was not effective in the reduction of PDAI score, but perianal discharge was reduced significantly [35].

Immunomodulatory agents

Thiopurines

No randomized controlled trials have evaluated the effectiveness of thiopurines for the treatment of perianal complex fistulas. Available data come from case series and from a meta-analysis of five randomized, placebo-controlled trials that assessed perianal fistula closure as secondary endpoint. In those, thiopurines (azathioprine 2-3 mg/kg and 6-mercaptopurine 1.5 mg/kg) seemed effective in inducing remission of perianal fistulas (odds ratio 4.44, 95% CI 1.5-13.20) [36] (Table 4). Even though thiopurines may be effective, this may take weeks or even months. Therefore, some studies have evaluated their role in combination with antibiotics or anti-TNF agents. A prospective trial evaluated the role of azathioprine in maintaining response after 8 weeks of antibiotics (ciprofloxacin or metronidazole), finding a higher response rate in those patients who were maintained on azathioprine after antibiotics withdrawal (48% vs. 15%, P=0.03) [32]. Studies of thiopurines in combination with IFX indicate that they may have a beneficial role in improving response. Despite the lack of controlled trials, ECCO guidelines recommend antibiotics with surgical drainage and maintenance therapy with thiopurines as first-line therapy for CPCD [3].

They should probably be used for facilitating and maintaining response in combination with anti-TNF agents.

Calcineurin inhibitors

Tacrolimus (0.2 mg/kg/day) in a small placebo-controlled trial was shown to be effective in improving symptoms (43% vs. 8%, P<0.05), but not in achieving complete fistula closure [37]. A more recent study evaluated the role of tacrolimus in severe CD intolerant or unresponsive to anti-TNF agents [38]. It included 15 patients with perianal fistulas, and a milder discharge was observed in five of them. Tacrolimus levels of 10-15 ng/mL were associated with better therapeutic results, with avoidance or delay of surgery. In patients not responding to anti-TNF therapy, tacrolimus may be used as rescue therapy before considering an aggressive surgical option.

In a retrospective study, intravenous cyclosporine followed by oral cyclosporine achieved complete closure in 4 of 13 patients, but the response was lost after drug discontinuation [39]. Due to the limited data, this drug is not a clear therapeutic option in CPCD.

Other

Small case series suggest that methotrexate may be effective for fistulizing CD [40]. However, it has not been specifically studied in CPCD; therefore, methotrexate can not be recommended nowadays.

Thalidomide has been used as a rescue therapy, given its ability to inhibit TNF- α , interferon- γ and interleukin (IL)-12,

Table 4 Immunomodulatory agents trials, meta-analysis or systematic reviews for fistulizing Crohn's disease

Authors and study design	Group 1	Group 2	Results
Pearson <i>et al</i> [36] Meta-analysis: nine randomized, placebo-controlled trials of azathioprine or 6-mercaptopurine therapy	Azathioprine or 6-mercaptopurine	Placebo	Fistulas improved with azathioprine or 6-mercaptopurine therapy (odds ratio 4.44; 95% CI 1.50 to 13.20)
Sandborn <i>et al</i> [37] Multicenter, prospective, double-blind, placebo-controlled study (n=48)	Oral tacrolimus (0.20 mg/kg/day) for 10 weeks	Placebo for 10 weeks	Tacrolimus 43% response vs. placebo 8% (P=0.004)
Cat <i>et al</i> [39] Retrospective (n=20)	Intravenous cyclosporine (4 mg/kg/day) for the first week, followed by oral cyclosporine at 8 mg/kg/day	No comparison arm	80% patients had symptomatic improvements on days 15 and 30 At 3, 6, 7, and 20 months 45% of fistulas were closed
Yang <i>et al</i> [41] Systematic review: 4 case series (n=40)	Thalidomide (50-300 mg/day)	No comparison arm	25% achieved remission, 27.5% partial response and 35% withdrew from the study due to adverse events

95% CI, 95% confidence interval

among others. It has been evaluated in uncontrolled studies for refractory CD, and some of these included patients with perianal fistulas. In 2015, Yang *et al* performed a systematic review of its efficacy in IBD [41]. They included 4 case series with a total of 40 patients with PCD who were treated with thalidomide (50-300 mg/day) as induction therapy. Ten patients achieved complete remission, 11 had a partial response, while five patients had no response. The remaining 14 subjects had to stop thalidomide because of side effects. Case reports and case series have reported some benefit of mycophenolate mofetil, but neither this nor thalidomide can be recommended for standard clinical practice.

Biological therapy

Anti-TNF agents

Anti-TNF agents have achieved the best available evidence for the treatment of CPCD. However, there are still some aspects regarding their use that require further evaluation, such as the need for concomitant antibiotics, thiopurines and seton placement. Even though anti-TNF agents are recommended by ECCO guidelines as second-line therapy for induction and maintenance treatment in patients refractory to thiopurines and antibiotics [3], most experts advocate a “top-down” strategy with anti-TNF as the initial treatment of choice for induction therapy in CPCD [18]. Antibiotics should probably be used concomitantly in induction and thiopurines in maintenance therapy, which should be maintained for at least one year. Rates around 11% of perianal abscess formation under anti-TNF therapy have been described [42] (Table 5). Consequently, it is important to drain abscesses prior to treatment in order to avoid septic complications and optimize therapeutic results.

IFX is the only medical treatment that has proved to be effective in inducing the closure of complex perianal fistulas in

a randomized controlled trial specifically designed and powered for this endpoint. In that study, 5 or 10 mg/kg of IFX at weeks 0, 2 and 6 achieved a response in 62% of patients, compared to 26% in the placebo group. Complete closure of all fistulas was observed in 55% of patients receiving the 5 mg/kg dose compared to 13% in the placebo group [42]. Another randomized placebo-controlled trial evaluated the efficacy of IFX in maintenance therapy (5 mg/kg every 8 weeks for one year) in patients who had previously responded to IFX induction, finding that 36% of patients had a complete absence of draining fistulas at week 54 compared to 19% in the placebo group (P=0.009) [43]. Other non-controlled studies have reported good results for IFX as induction and maintenance therapy, with rates of complete cessation of fistula drainage ranging from 13-90% [44]. Maintenance therapy with IFX significantly reduces hospitalizations and surgeries, and should be used by default [45]. As discussed above, antibiotics may be useful as adjuvant therapy with anti-TNF agents. Even though IFX therapy offers the best results, there is a discrepancy between clinical remission and persistent fistula activity on imaging. MRI or ultrasound studies show that fistula healing only occurs in a small minority and that tracks persist. In one study, 54% of patients had a clinical response with cessation of drainage, but fistula inactivity was detected on ultrasound in only 18% [46]. This may contribute to the high rate of recurrence when treatment is stopped after one year in patients with complex fistula in clinical remission, suggesting the need for a longer period of treatment and the use of image studies before considering treatment discontinuation. Interestingly, a recent study presented at Digestive Disease Week 2016 suggests that the IFX levels needed for fistula healing are greater than those needed for mucosal healing [47].

Regarding ADA, complete closure and fistula improvement was evaluated as a secondary endpoint in three randomized controlled trials comparing this drug to placebo. The most recent one included 117 patients with actively draining perianal fistulas, who were randomized to

Table 5 Biological therapy trials for fistulizing Crohn's disease

Authors and study design	Group 1	Group 2	Results
Present <i>et al</i> [42] Multicenter, prospective, double-blind, placebo-controlled study (n=94)	Infliximab 5 mg/kg at 0, 2 and 6 weeks or infliximab 10 mg/kg at 0, 2 and 6 weeks	Placebo	Complete closure of all fistulas: 5 mg/kg dose: 55%, 10 mg/kg dose: 38% and placebo: 13%
Sands <i>et al</i> [43] Multicenter, prospective, double-blind, placebo-controlled study (n=195)	Infliximab 5 mg/kg every 8 weeks for 54 weeks	Placebo every 8 weeks for 54 weeks	Cessation of drainage: Infliximab group: 36% vs. placebo groups 19% (P=0.009)
Schwartz <i>et al</i> [44] Retrospective (n=21)	Ciprofloxacin (1000 mg/day), azathioprine (2-2.5 mg/kg/day) or 6-mercaptopurine (1-1.5 mg/kg/day) and infliximab (5 mg/kg at 0, 2 and 6 week and then every 8 weeks)	No comparison arm	Cessation of drainage: initial 86% and long-term 76%
Colombel <i>et al</i> [48] Multicenter, prospective, double-blind, placebo-controlled study (n=117)	Adalimumab (160/80 mg at 0/2 weeks) and then 40 mg weekly	Adalimumab (160/80 mg at 0/2 weeks) and then placebo	Cessation of drainage: Adalimumab group: 33% and placebo group: 13% (P=0.016)
Schreiber <i>et al</i> [49] Multicenter, prospective, double-blind, placebo-controlled study (n=58)	Certolizumab pegol (400 mg monthly)	Placebo	Cessation of drainage: Certolizumab pegol group: 36% vs. placebo group: 17% (P=0.038)
Sandborn <i>et al</i> [50] Multicenter, prospective, double-blind, placebo-controlled study (n=165)	Vedolizumab (300 mg) every 4 or 8 weeks	Placebo	Cessation of drainage: Vedolizumab group: 41.2% vs. placebo group 11% (P=0.03)

receive ADA or placebo for one year after induction with ADA; fistula remission was higher in the ADA group at week 56 (33% vs. 13%, $P < 0.02$) [48].

There are no randomized placebo controlled trials specifically designed to examine the efficacy of certolizumab pegol in perianal disease but its efficacy has been reported as a secondary endpoint. One trial evaluated maintenance therapy with certolizumab pegol versus placebo after response to induction with certolizumab, finding that 36% of patients in the treatment group achieved complete closure of perianal fistulas versus 17% in the placebo group ($P = 0.038$) [49].

Other biological therapies

There is limited data regarding the efficacy of vedolizumab in perianal disease, with inconclusive results. A randomized controlled trial designed to evaluate the efficacy of vedolizumab in CD found that vedolizumab every 8 weeks achieved a significantly higher rate of draining fistula closure compared to placebo (41.2% vs. 11%, $P = 0.03$) [50].

Ustekinumab is an anti-IL-12/IL-23 monoclonal antibody that has shown its efficacy in Crohn's disease in phase IIb and phase III clinical trials; unfortunately, these trials do not address its role in PCD [51]. To date, the most extensive data come from a recently published observational study. In 2016 Wils *et al* performed a multicenter retrospective analysis that included 12 patients with PCD; 8 of them experienced clinical improvement, as defined by physician's global assessment, the probability of remaining corticosteroid/surgery free, and no additional immunosuppression [52].

Other treatments

In recent decades, several new kinds of treatments have emerged in the hope of offering an alternative for those patients unresponsive to standard therapy. However, their place in the therapeutic algorithm and their real-world clinical applicability remain to be seen, since most of the available data come from studies with a high risk of bias.

Hyperbaric oxygen therapy (HOT)

HOT involves breathing 100% oxygen while under increased atmospheric pressure. This leads to an increase in the plasma O_2 partial pressure, thus enhancing oxygenation of hypoxic bowel tissues and also of non-healing perianal fistulas. In addition, it has been reported that HOT may have immunomodulatory properties, reducing IL-1, IL-2 and TNF- α levels [53] and upregulating molecular pathways (hypoxia-inducible factor-1, heme oxygenase-1) with an essential role in hypoxia tolerance [54].

In 2014, Dulai *et al* performed a systematic review of the efficacy and safety of HOT in IBD [55]. They incorporated data from 17 different studies, most of which were case reports, with only one randomized clinical trial. In their analysis they included 40 patients with PCD for a median of 2 years prior to initiation of HOT; 21 had fistulas, with a predominance of complex fistulas. Most of these patients responded poorly to 5-aminosalicylic acid, steroids and immunomodulatory therapy. The overall response rate was 88% (18/40 complete healing, 17/40 partial healing), while two patients abandoned the treatment because of side effects. It should be highlighted

that there was high heterogeneity in the assessment of response to therapy, symptom evaluation, number of sessions and time of follow up.

Adverse effects are uncommon (0.01%) and it seems that HOT is better tolerated than in other indications, such as radiation proctitis (0.2%). Eardrum perforation and psychological intolerance (claustrophobia) are the most frequent side effects. Pneumothorax, myopia, bowel perforation and seizures have also been described [55].

Since the completion of this systematic review no further relevant data have emerged.

Mesenchymal stem cells (MSCs)

MSCs are non-hematopoietic multipotent cells with powerful anti-inflammatory, immunomodulatory and fibroblast-like healing properties. Currently, both allogenic and autologous MSCs derived from fat or bone marrow have been used in PCD [56]. There are already available data from several phase II clinical trials, confirming that this therapeutic approach is safe and probably useful for some patients. Subjects included in these studies were highly heterogeneous, most of them refractory to thiopurines and anti-TNF drugs, and obtained variable rates of fistula closure ranging from 37-85%. The most common route of administration was intralesional local injection, with only one study using the intravenous route [56]. In 2015 Ciccocioppo *et al* reported the outcomes of 10 patients prospectively recorded over a period of 7 years. The probability of fistula relapse-free survival was 88% at 1 year, 50% at 2 years, and 37% with no adverse effects; supporting the effectiveness and long-term safety of this procedure [57]. More recently, a randomized phase III controlled trial has shown good effectiveness in patients who have failed conventional or biologic treatments [58]. This trial included 212 patients, randomized to receive intralesional injection of allogeneic adipose-derived stem cells or saline solution (placebo); fistula remission was higher in stem cells group at week 24 (50% vs. 34%, $P = 0.024$). Though MSC therapy appears promising, there are still key questions to be answered, such as the ideal type of MSC, the dosage of cells required, the number of injections, and its long-term efficacy.

Fibrin glue injection

Fibrin glue injection is an attractive and simple technique that uses the activation of thrombin to form a fibrin clot that mechanically seals the fistula tract. The clot undergoes gradual fibrinolysis while activating tissue-healing mechanisms to permanently close the fistula tract. Uncontrolled reports showed encouraging results, with success rates ranging from 60-85% [59]. The most relevant study was published in 2010, when Grimaud *et al* performed a multicenter, open-label, randomized controlled trial that included 77 patients with a CD Activity Index (CDAI) score ≤ 250 and fistulas between the anus (or low rectum) and perineum, vulva, or vagina, which drained for more than 2 months [60]. Clinical remission at

week 8 was observed in 38% of the fibrin glue group compared with 16% in the observation group; the subgroup with complex fistulas obtained inferior results. The authors remarked on the patients' low CDAI score and hypothesized that fibrin glue is a purely mechanical treatment that should take place only after inflammation has been controlled.

Anal fistula plug

Currently there are two available methods: Surgisis® and GORE BioA® plug. The most widespread is Surgisis®, a bioabsorbable plug composed of lyophilized porcine-derived small intestinal submucosa. The GORE BioA® plug is made of absorbable synthetic compounds with a cone-shaped design, fused to a flat disc at one end, in order to allow easy fixation at the internal fistula opening. A recent systematic review of the literature that included 8 nonrandomized prospective studies and 4 retrospective cohorts gathered 84 patients with an average age of 45 and a median follow-up time of 9 months. Overall, the success rates of Surgisis® and GORE® BIOA® brand plugs were 48/80 (60%, 95% CI 48-71%) and 1/4 (25%, 95% CI 1-81%) respectively; inferior results when compared with non-CD anal fistulas. The rate of recurrence was analyzed in 5 original papers (13.6%). The success rate was inferior in those treated with preoperative immunomodulators [61].

These promising results have not been reproduced in the first multicenter, open-label, randomized controlled trial to date. In 2016 Senejoux *et al* compared the Surgisis® plug with seton removal alone (control group) in 106 CD patients with non- or only mildly active disease. No difference was found in terms of fistula closure and adverse events [62].

Fistula laser closure

This is a new sphincter-saving technique that uses a diode laser (FiLaC™) to destroy the fistula epithelium and obliterate the whole fistula tract. Laser energy promotes shrinkage of tissue and progressive sealing of fistulas. Wilhelm published the first pilot study in 2011 with 11 patients (none with IBD), achieving 81.8% primary fistula healing with only one minor adverse event [63]. Giamundo *et al* in 2015 carried out a retrospective single-institution study of 45 patients; two patients with PCD were successfully managed [64].

Carbon dioxide laser ablation therapy has also shown favorable results in small uncontrolled retrospective cohorts [65].

Malignant transformation in perianal fistulas

To our knowledge, no large population-based studies have been performed to assess the true prevalence of fistula-associated anal carcinoma (FAAC). Available data are from case reports, retrospective cohorts and a systematic review of 2010 that compiled 61 cases [66,67]. This is considered

an unusual entity, with an estimated prevalence of 0.004-0.7% [68]. FAAC arises in patients with long-standing fistulas; most cases have been documented in subjects with a disease duration over 15 years. Its exact pathogenesis is unclear; it has been postulated that chronic inflammation, long-term immunosuppression, infection by human papillomavirus, and smoking may all be involved in its genesis [66,68,69]. Adenocarcinoma, particularly the mucin-producing variant, is by far the most common histological type; squamous cell carcinoma has also been reported [66]. The majority of tumors are diagnosed at an advanced stage, since FAAC is a rapidly developing malignancy and symptoms are usually absent or non-specific. Anal discharge, fistula draining, painful defecation or other worsening symptoms should all raise suspicion among patients with long-standing perianal disease and MRI/EUA should be considered. Some authors advocate yearly surveillance in patients with more than a 10-year history of perianal disease [69]; however, others do not recommend this approach because of its low prevalence and the lack of a validated screening algorithm [66,68].

Prognosis after surgery is usually poor, with a high rate of postoperative relapse, especially if perirectal lymph nodes are affected. Adjuvant chemoradiotherapy is highly controversial and its use should only be considered on an individual basis. There is no good evidence to support its routine use. In addition it has been suggested that mucinous adenocarcinoma does not respond to this therapy [69].

Concluding remarks

The management of CPCD requires the collaboration of radiologists, colorectal surgeons and gastroenterologists. Diagnosis should include a careful history and physical examination, but these must be complemented. MRI and EUS are the mainstay of imaging evaluation, and EUA remains the gold standard for diagnosing and classifying this disease. The combination of EUA with MRI or EUS improves accuracy to reach 100%. Before initiating immunosuppressive treatment, it is important to control sepsis with antibiotics, surgical drainage, or both. Associated proctitis, if present, must be treated to improve the effectiveness of other therapies. Despite the lack of controlled trials, antibiotics as adjuvant therapy to immunomodulators and surgical therapy are the recommended treatment for CPCD. Anti-TNF agents have the best available evidence record in the treatment of CPCD, so they can be used as the first-line treatment associated with surgical therapy.

The future perspectives in the area of perianal CD could probably come from two sources. We are getting the first data about new drugs in the management of CD, and it would undoubtedly be a major bonus if any of them was revealed as especially active in this context. Data on the efficacy of vedolizumab and ustekinumab do not look especially bright, but new mechanisms of action are continuously being explored. The other possible source is the expansion of local therapies, and in this realm the use of stem cells seems the most likely

source for positive results. Other more speculative domains could include the identification of a genetic predisposition to suffer perianal CD, advances in diagnostic techniques, and new studies on the long-term efficacy of therapeutic strategies (as opposed to single drugs, as is generally explored in pivotal studies). These patients carry a heavy personal burden, and their disease adds a significant burden to the spending on hospital consultations, drug therapy and surgery costs. Therefore, let us sincerely hope that the next years bring good news in the management of this condition.

References

1. Van Assche G, Dignass A, Panes J, *et al*; European Crohn's and Colitis Organisation (ECCO). The second European evidence-based Consensus on the diagnosis and management of Crohn's disease: Definitions and diagnosis. *J Crohns Colitis* 2010;4:7-27.
2. Chaparro M, Zanotti C, Burgueño P, *et al*. Health care costs of complex perianal fistula in Crohn's disease. *Dig Dis Sci* 2013;58:3400-3406.
3. Van Assche G, Dignass A, Reinisch W, *et al*; European Crohn's and Colitis Organisation (ECCO). The second European evidence-based Consensus on the diagnosis and management of Crohn's disease: Special situations. *J Crohns Colitis* 2010;4:63-101.
4. Sandborn WJ, Fazio VW, Feagan BG, Hanauer SB; American Gastroenterological Association Clinical Practice Committee. AGA technical review on perianal Crohn's disease. *Gastroenterology* 2003;125:1508-1530.
5. Bell SJ, Williams AB, Wiesel P, Wilkinson K, Cohen RC, Kamm MA. The clinical course of fistulating Crohn's disease. *Aliment Pharmacol Ther* 2003;17:1145-1151.
6. Molendijk I, Nuij VJ, van der Meulen-de Jong AE, van der Woude CJ. Disappointing durable remission rates in complex Crohn's disease fistula. *Inflamm Bowel Dis* 2014;20:2022-2028.
7. Saro C, da la Coba C, Casado MA, Morales JM, Otero B. Resource use in patients with Crohn's disease treated with infliximab. *Aliment Pharmacol Ther* 2007;26:1313-1323.
8. Zwintscher NP, Shah PM, Argawal A, *et al*. The impact of perianal disease in young patients with inflammatory bowel disease. *Int J Colorectal Dis* 2015;30:1275-1279.
9. Riss S, Schwameis K, Mittlböck M, *et al*. Sexual function and quality of life after surgical treatment for anal fistulas in Crohn's disease. *Tech Coloproctol* 2013;17:89-94.
10. Parks AG, Gordon PH, Hardcastle JD. A classification of fistula-in-ano. *Br J Surg* 1976;63:1-12.
11. Panes J, Bouhnik Y, Reinisch W, *et al*. Imaging techniques for assessment of inflammatory bowel disease: joint ECCO and ESGAR evidence-based consensus guidelines. *J Crohns Colitis* 2013;7:556-585.
12. Navarro-Luna A, García-Domingo MI, Rius-Macías J, Marco-Molina C. Ultrasound study of anal fistulas with hydrogen peroxide enhancement. *Dis Colon Rectum* 2004;47:108-114.
13. Zawadzki A, Starck M, Bohe M, Thorlacius H. A unique 3D endoanal ultrasound feature of perianal Crohn's fistula: the 'Crohn ultrasound fistula sign'. *Colorectal Dis* 2012;14:e608-e611.
14. Siddiqui MR, Ashrafian H, Tozer P, *et al*. A diagnostic accuracy meta-analysis of endoanal ultrasound and MRI for perianal fistula assessment. *Dis Colon Rectum* 2012;55:576-585.
15. Maconi G, Ardizzone S, Greco S, Radice E, Bezzio C, Bianchi Porro G. Transperineal ultrasound in the detection of perianal and rectovaginal fistulae in Crohn's disease. *Am J Gastroenterol* 2007;102:2214-2219.

16. Schwartz DA, Wiersema MJ, Dudiak KM, *et al.* A comparison of endoscopic ultrasound, magnetic resonance imaging, and exam under anesthesia for evaluation of Crohn's perianal fistulas. *Gastroenterology* 2001;**121**:1064-1072.
17. Sahni VA, Ahmad R, Burling D. Which method is best for imaging of perianal fistula? *Abdom Imaging* 2008;**33**:26-30.
18. Gecse KB, Bemelman W, Kamm MA, *et al*; World Gastroenterology Organization International Organisation for Inflammatory Bowel Diseases IOIBD European Society of Coloproctology and Robarts Clinical Trials. A global consensus on the classification, diagnosis and multidisciplinary treatment of perianal fistulising Crohn's disease. *Gut* 2014;**63**:1381-1392.
19. Irvine EJ. Usual therapy improves perianal Crohn's disease as measured by a new disease activity index. McMaster IBD Study Group. *J Clin Gastroenterol* 1995;**20**:27-32.
20. Losco A, Viganò C, Conte D, Cesana BM, Basilisco G. Assessing the activity of perianal Crohn's disease: comparison of clinical indices and computer-assisted anal ultrasound. *Inflamm Bowel Dis* 2009;**15**:742-749.
21. Schwartz DA, Ghazi LJ, Regueiro M, *et al*; Crohn's & Colitis Foundation of America, Inc. Guidelines for the multidisciplinary management of Crohn's perianal fistulas: summary statement. *Inflamm Bowel Dis* 2015;**21**:723-730.
22. Van Assche G, Vanbeckevoort D, Bielen D, *et al.* Magnetic resonance imaging of the effects of infliximab on perianal fistulizing Crohn's disease. *Am J Gastroenterol* 2003;**98**:332-339.
23. Makowiec F, Jehle EC, Becker HD, Starlinger M. Perianal abscess in Crohn's disease. *Dis Colon Rectum* 1997;**40**:443-450.
24. de Groof EJ, Sahami S, Lucas C, Ponsioen CY, Bemelman WA, Buskens CJ. Treatment of perianal fistula in Crohn's disease: a systematic review and meta-analysis comparing seton drainage and anti-tumour necrosis factor treatment. *Colorectal Dis* 2016;**18**:667-675.
25. Marzo M, Felice C, Pugliese D, *et al.* Management of perianal fistulas in Crohn's disease: an up-to-date review. *World J Gastroenterol* 2015;**21**:1394-1403.
26. Hong MK, Craig Lynch A, Bell S, *et al.* Faecal diversion in the management of perianal Crohn's disease. *Colorectal Dis* 2011;**13**:171-176.
27. Pellino G, Selvaggi F. Surgical treatment of perianal fistulizing Crohn's disease: from lay-open to cell-based therapy. An overview. *ScientificWorldJournal* 2014;**2014**:146281.
28. Cattan P, Bonhomme N, Panis Y, *et al.* Fate of the rectum inpatients undergoing total colectomy for Crohn's disease. *Br J Surg* 2001;**89**:454-459.
29. Wang JY, Hart SL, Wilkowski KS, *et al.* Gender-specific differences in pelvic organ function after proctectomy for inflammatory bowel disease. *Dis Colon Rectum* 2011;**54**:66-76.
30. de Groof EJ, Cabral VN, Buskens CJ, Morton DG, Hahnloser D, Bemelman WA; research committee of the European Society of Coloproctology. Systematic review of evidence and consensus on perianal fistula: an analysis of national and international guidelines. *Colorectal Dis* 2016;**18**:O119-34.
31. Thia KT, Mahadevan U, Feagan BG, *et al.* Ciprofloxacin or metronidazole for the treatment of perianal fistulas in patients with Crohn's disease: a randomized, double-blind, placebo-controlled pilot study. *Inflamm Bowel Dis* 2009;**15**:17-24.
32. Dejaco C, Harrer M, Waldhoer T, Miehsler W, Vogelsang H, Reinisch W. Antibiotics and azathioprine for the treatment of perianal fistulas in Crohn's disease. *Aliment Pharmacol Ther* 2003;**18**:1113-1120.
33. West RL, van der Woude CJ, Hansen BE, *et al.* Clinical and endosonographic effect of ciprofloxacin on the treatment of perianal fistulae in Crohn's disease with infliximab: a double-blind placebo-controlled study. *Aliment Pharmacol Ther* 2004;**20**:1329-1336.
34. Dewint P, Hansen BE, Verhey E, *et al.* Adalimumab combined with ciprofloxacin is superior to adalimumab monotherapy in perianal fistula closure in Crohn's disease: a randomised, double-blind, placebo controlled trial (ADAFI). *Gut* 2014;**63**:292-299.
35. Maeda Y, Ng SC, Durdey P, *et al*; Topical Metronidazole in Perianal Crohn's Study Group. Randomized clinical trial of metronidazole ointment versus placebo in perianal Crohn's disease. *Br J Surg* 2010;**97**:1340-1347.
36. Pearson DC, May GR, Fick GH, Sutherland LR. Azathioprine and 6-mercaptopurine in Crohn disease. A meta-analysis. *Ann Intern Med* 1995;**123**:132-142.
37. Sandborn WJ, Present DH, Isaacs KL, *et al.* Tacrolimus for the treatment of fistulas in patients with Crohn's disease: a randomized, placebo-controlled trial. *Gastroenterology* 2003;**125**:380-388.
38. Gerich ME, Pardi DS, Bruining DH, Kammer PP, Becker BD, Tremaine WT. Tacrolimus salvage in anti-tumor necrosis factor antibody treatment-refractory Crohn's disease. *Inflamm Bowel Dis* 2013;**19**:1107-1111.
39. Cat H, Sophani I, Lemann M, Modigliani R, Solue JC. Cyclosporin treatment of anal and perianal lesions associated with Crohn's disease. *Turk J Gastroenterol* 2003;**14**:121-127.
40. Mahadevan U, Marion JF, Present DH. Fistula response to methotrexate in Crohn's disease: a case series. *Aliment Pharmacol Ther* 2003;**18**:1003-1008.
41. Yang C, Singh P, Singh H, Le ML, El-Matary W. Systematic review: thalidomide and thalidomide analogues for treatment of inflammatory bowel disease. *Aliment Pharmacol Ther* 2015;**41**:1079-1093.
42. Present DH, Rutgeerts P, Targan S, *et al.* Infliximab for the treatment of fistulas in patients with Crohn's disease. *N Engl J Med* 1999;**340**:1398-1405.
43. Sands BE, Anderson FH, Bernstein CN, *et al.* Infliximab maintenance therapy for fistulizing Crohn's disease. *N Engl J Med* 2004;**350**:876-885.
44. Schwartz DA, Ghazi LJ, Regueiro M. Guidelines for medical treatment of Crohn's perianal fistulas: critical evaluation of therapeutic trials. *Inflamm Bowel Dis* 2015;**21**:737-752.
45. Lichtenstein GR, Yan S, Bala M, Blank M, Sands BE. Infliximab maintenance treatment reduces hospitalizations, surgeries, and procedures in fistulizing Crohn's disease. *Gastroenterology* 2005;**128**:862-869.
46. Ardizzone S, Maconi G, Colombo E, Manzionna G, Bollani S, Bianchi Porro G. Perianal fistulae following infliximab treatment: clinical and endosonographic outcome. *Inflamm Bowel Dis* 2004;**10**:91-96.
47. Yarur A, Kanagala V, Stein D, *et al.* Higher infliximab trough levels are associated with a higher rate of perianal fistula healing in patients with Crohn's disease. *Gastroenterology* 2016;**4**:S105-S106.
48. Colombel JF, Schwartz DA, Sandborn WJ, *et al.* Adalimumab for the treatment of fistulas in patients with Crohn's disease. *Gut* 2009;**58**:940-948.
49. Schreiber S, Lawrance IC, Thomsen O, Hanauer SB, Bloomfield R, Sandborn WJ. Randomised clinical trial: certolizumab pegol for fistulas in Crohn's disease - subgroup results from a placebo-controlled study. *Aliment Pharmacol Ther* 2011;**33**:185-193.
50. Sandborn WJ, Feagan BG, Rutgeerts P, *et al*; GEMINI 2 Study Group. Vedolizumab as induction and maintenance therapy for Crohn's disease. *N Engl J Med* 2013;**369**:711-721.
51. Simon EG, Ghosh S, Iacucci M, Moran GW. Ustekinumab for the treatment of Crohn's disease: can it find its niche? *Therap Adv Gastroenterol* 2016;**9**:26-36.
52. Wils P, Bouhnik Y, Michetti P, *et al*; Groupe d'Etude Thérapeutique des Affections Inflammatoires du Tube Digestif. Subcutaneous ustekinumab provides clinical benefit for two-thirds of patients with Crohn's disease refractory to anti-tumor necrosis factor

- agents. *Clin Gastroenterol Hepatol* 2016;**14**:242-250.e1-e2.
53. Weisz G, Lavy A, Adir Y, *et al*. Modification of in vivo and in vitro TNF-alpha, IL-1, and IL-6 secretion by circulating monocytes during hyperbaric oxygen treatment in patients with perianal Crohn's disease. *J Clin Immunol* 1997;**17**:154-159.
 54. Al-Waili NS, Butler GJ. Effects of hyperbaric oxygen on inflammatory response to wound and trauma: possible mechanism of action. *ScientificWorldJournal* 2006;**6**:425-441.
 55. Dulai PS, Gleeson MW, Taylor D, Holubar SD, Buckey JC, Siegel CA. Systematic review: The safety and efficacy of hyperbaric oxygen therapy for inflammatory bowel disease. *Aliment Pharmacol Ther* 2014;**39**:1266-1275.
 56. Garcia-Olmo D, Schwartz DA. Cumulative evidence that mesenchymal stem cells promote healing of perianal fistulas of patients with Crohn's disease—going from bench to bedside. *Gastroenterology* 2015;**149**:853-857.
 57. Ciccocioppo R, Gallia A, Sgarella A, Kruzliak P, Gobbi PG, Corazza GR. Long-term follow-up of Crohn disease fistulas after local injections of bone marrow-derived mesenchymal stem cells. *Mayo Clin Proc* 2015;**90**:747-755.
 58. Panés J, García-Olmo D, Van Assche G, *et al*. Expanded allogeneic adipose-derived mesenchymal stem cells (Cx601) for complex perianal fistulas in Crohn's disease: a phase 3 randomised, double-blind controlled trial. *Lancet* 2016;**388**:1281-1290.
 59. Vitton V, Gasmi M, Barthet M, Desjeux A, Orsoni P, Grimaud JC. Long-term healing of Crohn's anal fistulas with fibrin glue injection. *Aliment Pharmacol Ther* 2005;**21**:1453-1457.
 60. Grimaud JC, Munoz-Bongrand N, Siproudhis L, *et al*; Groupe d'Etude Thérapeutique des Affections Inflammatoires du Tube Digestif. Fibrin glue is effective healing perianal fistulas in patients with Crohn's disease. *Gastroenterology* 2010;**138**:2275-2281, 2281.e1.
 61. Nasseri Y, Cassella L, Berns M, Zaghiyan K, Cohen J. The anal fistula plug in Crohn's disease patients with fistula-in-ano: a systematic review. *Colorectal Dis* 2016;**18**:351-356.
 62. Senéjoux A, Siproudhis L, Abramowitz L, *et al*; Groupe d'Etude Thérapeutique des Affections Inflammatoires du tube Digestif [GETAID]. Fistula plug in fistulising ano-perineal Crohn's disease: a randomised controlled trial. *J Crohns Colitis* 2016;**10**:141-148.
 63. Wilhelm A. A new technique for sphincter-preserving anal fistula repair using a novel radial emitting laser probe. *Tech Coloproctol* 2011;**15**:445-449.
 64. Giamundo P, Esercizio L, Geraci M, Tibaldi L, Valente M. Fistula-tract laser closure (FiLaC™): long-term results and new operative strategies. *Tech Coloproctol* 2015;**19**:449-453.
 65. Moy J, Bodzin J. Carbon dioxide laser ablation of perianal fistulas in patients with Crohn's disease: experience with 27 patients. *Am J Surg* 2006;**191**:424-427.
 66. Thomas M, Bienkowski R, Vandermeer TJ, Trostle D, Cagir B. Malignant transformation in perianal fistulas of Crohn's disease: a systematic review of literature. *J Gastrointest Surg* 2010;**14**:66-73.
 67. Baars JE, Kuipers EJ, Dijkstra G, *et al*; Initiative for Crohn and Colitis. Malignant transformation of perianal and enterocutaneous fistulas is rare: results of 17 years of follow-up from The Netherlands. *Scand J Gastroenterol* 2011;**46**:319-325.
 68. Alcalde-Vargas A, Trigo-Salado C, Leo-Carnerero E, Castell-Monsalve FJ, Mateo-Vico O, Márquez-Galán JL. Severe perianal disease degenerated to adenocarcinoma. Is close monitoring of long-term perianal disease necessary? *Rev Esp Enferm Dig* 2013;**105**:115-116.
 69. Iesalnieks I, Gaertner WB, Glass H, *et al*. Fistula-associated anal adenocarcinoma in Crohn's disease. *Inflamm Bowel Dis* 2010;**16**:1643-1648.