

Value of 3 Tesla diffusion-weighted magnetic resonance imaging for assessing liver fibrosis

Lavrentios Papalavrentios^a, Emmanouil Sinakos^a, Danai Chourmouzi^b, Prodromos Hytioglou^c, Konstantinos Drevelegas^b, Manos Constantinides^b, Antonios Drevelegas^b, Jayant Talwalkar^d, Evangelos Akriviadis^a

University of Thessaloniki, Greece; Interbalkan Medical Center, Thessaloniki, Greece; Mayo Clinic Rochester, Rochester, MN, USA

Abstract

Background Limited data are available regarding the role of magnetic resonance imaging (MRI), particularly the new generation 3 Tesla technology, and especially diffusion-weighted imaging (DWI) in predicting liver fibrosis. The aim of our pilot study was to assess the clinical performance of the apparent diffusion coefficient (ADC) of liver parenchyma for the assessment of liver fibrosis in patients with non-alcoholic fatty liver disease (NAFLD).

Methods 18 patients with biopsy-proven NAFLD underwent DWI with 3 Tesla MRI. DWI was performed with single-shot echo-planar technique at b values of 0-500 and 0-1000 s/mm². ADC was measured in four locations in the liver and the mean ADC value was used for analysis. Staging of fibrosis was performed according to the METAVIR system.

Results The median age of patients was 52 years (range 23-73). The distribution of patients in different fibrosis stages was: 0 (n=1), 1 (n=7), 2 (n=1), 3 (n=5), 4 (n=4). Fibrosis stage was poorly associated with ADC at b value of 0-500 s/mm² (r= -0.30, P=0.27). However it was significantly associated with ADC at b value of 0-1000 s/mm² (r= -0.57, p=0.01). For this b value (0-1000 s/mm²) the area under receiver-operating characteristic curve was 0.93 for fibrosis stage ≥3 and the optimal ADC cut-off value was 1.16 × 10⁻³ mm²/s.

Conclusion 3 Tesla DWI can possibly predict the presence of advanced fibrosis in patients with NAFLD.

Keywords Liver fibrosis, non-alcoholic fatty liver, diffusion-weighted imaging, 3 Tesla

Ann Gastroenterol 2014; 27 (4): 1-6

Introduction

Non-alcoholic fatty liver disease (NAFLD) is currently the most prevalent cause of liver disease in Western countries. The development of non-alcoholic steatohepatitis (NASH) and fibrosis identifies a group with increased risk of liver-related

deaths due to cirrhosis or hepatocellular carcinoma. The prevalence of NAFLD is estimated between 20% and 30% in Western countries [1,2], rising to 90% in the morbidly obese patients [3]. NASH, the more advanced and clinically important form of NAFLD, is less common, with an estimated prevalence of 2-3% in the general population [4], and 37% in the morbidly obese [3].

Liver biopsy is currently the gold standard to guide therapeutic decisions and assess prognosis in patients with NAFLD. The development of non-invasive methods for liver fibrosis evaluation aims to reduce biopsy-related risk and cost and to facilitate improved monitoring of disease progression. Serological assays, such as Fibrotest, and radiological methods like transient elastography (Fibroscan, Echosens, France) are used increasingly to evaluate liver fibrosis in NAFLD and other chronic liver diseases. Magnetic resonance imaging (MRI) is being evaluated as a non-invasive method of liver fibrosis assessment as well. Recently, MR elastography demonstrated excellent diagnostic accuracy with sensitivity and specificity of 98% and 99% respectively for detecting all grades of fibrosis [5].

^a4th Internal Medicine Unit, University of Thessaloniki (Lavrentios Papalavrentios, Emmanouil Sinakos, Evangelos Akriviadis);

^bDepartment of Radiology, Interbalkan Medical Center, Thessaloniki (Danai Chourmouzi, Konstantinos Drevelegas, Manos Constantinides, Antonios Drevelegas); ^cDepartment of Pathology, University of Thessaloniki (Prodromos Hytioglou), Greece; ^dDivision of Gastroenterology and Hepatology, Mayo Clinic Rochester, Rochester, MN, USA (Jayant Talwalkar)

Conflict of Interest: None

Correspondence to: Lavrentios Papalavrentios, M.D., Samanidi 36, Panorama, Thessaloniki, Greece, Tel.: +30 2310 342046, Fax: +30 2310 471056, e-mail: lpapalavrentios@yahoo.com

Received 2 March 2014; accepted 20 July 2014

Another MRI technique, diffusion-weighted imaging (DWI), has been lately used for liver fibrosis assessment. Diffusion is a physical property, which describes the microscopic random movement of (water) molecules driven by their internal thermal energy. Diffusion is quantitatively reflected in a diffusion coefficient, the *apparent diffusion coefficient* (ADC, expressed in mm^2/s). Conflicting results regarding the reliability of DWI and apparent diffusion coefficient (ADC) values in liver fibrosis staging for patients with chronic liver disease are reported [6,7], while several studies have shown a decrease in hepatic ADC in liver cirrhosis [8-10].

The aim of our study was to assess the clinical performance of DWI performed with 3 Tesla MRI scanners for the assessment of liver fibrosis in patients with NAFLD.

Patients and methods

Patients

We included only patients with biopsy-proven NAFLD in this study. Patients with positive hepatitis B surface antigen, anti-hepatitis C virus antibody or histological evidence of concomitant liver disease were excluded from the study. Patients with alcohol consumption of more than 40 g/day were also excluded. All patients underwent percutaneous liver biopsy (LB) and then DWI within a 3-month interval. Anthropometric tests included body weight, body height, and waist circumference measurements. Body mass index (BMI) was calculated as weight (kg) divided by height (m) squared. On the day of liver biopsy, a fasting venous blood sample was taken for aspartate aminotransferase (AST), alanine aminotransferase (ALT), alkaline phosphatase (ALP), total bilirubin, albumin, glucose, total cholesterol, and triglycerides.

DWI

DWI was performed on a 3 Tesla MRI scanner (Signa HDxT, General Electric, Milwaukee) with the aid of 8 channel Torso phased-array coil. Diffusion was in all cases acquired with respiratory gating with a Single Shot Echo Planar Imaging (DW-EPI) pulse sequence. Parallel imaging with Array Spatial Sensitivity Encoding Technique (ASSET) factor of 2 was used to improve image quality. DWI was performed in the axial plane with tri-directional diffusion gradients using three b values, namely, 0, 500, and 1000 s/mm^2 . The repetition time (TR) was on the average 10,288 ms (between 8,571 and 13,330), echo time (TE) between 63.7 – 67.9 ms, slice thickness 6 mm, gap between slices 1 mm, matrix 128×128 , field of view 400 mm, number of excitations 4. The total acquisition time was on the average 4-5 min. The ADC maps were calculated by commercial workstation software (GE Healthcare) over four random locations within the liver using 1-2 cm^2 regions of interest away from the intrahepatic vasculature. Mean ADC values were used for analysis (Fig. 1).

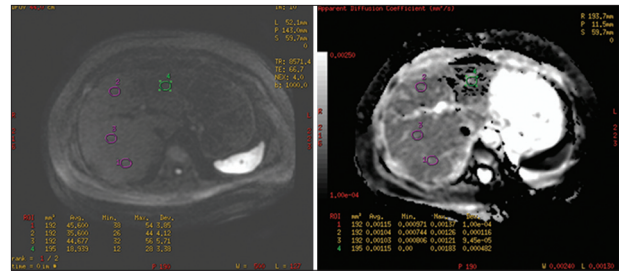


Figure 1 Diffusion-weighted image and apparent diffusion coefficient map obtained at b value of 0-1000 s/mm^2 in a 63-year-old woman with non-alcoholic fatty liver disease and fibrosis stage 3

Liver biopsy

LB procedures were performed by experienced physicians using the intercostal approach with 1.6 and 1.8 mm diameter Menghini needles. All biopsies had at least 1.5 cm length and were evaluated by experienced liver pathologists using the METAVIR scoring system for staging fibrosis from 0 to 4: stage 0=absence of fibrosis; stage 1=perisinusoidal or portal; stage 2=perisinusoidal and portal/periportal; stage=3 septal or bridging fibrosis; and stage 4=cirrhosis. Grade of liver steatosis was defined according to Kleiner *et al*: 0=steatosis <5%, 1=5% to 33%, 2=steatosis >33%-66%, 3=steatosis >66% [11].

Statistical analysis

Continuous variables were presented as means \pm standard deviation or median (range) and frequency data were presented as number and percentage. The correlations of ADC with different variables were explored using the Spearman's ρ correlation. The performance of ADC was assessed using the receiver operator characteristic (ROC) curve. Based on the ROC curve, a cutoff value was designated for ADC to maximize the sensitivity and specificity of the assay.

Results

Table 1 summarizes the baseline patients' characteristics. 18 patients were included in our study. The median age of our patients was 52 years (range 23-73). The mean BMI was 28.1 kg/m^2 (range 20.3-38.2). 78% percent of subjects were male. The median values for AST, ALT, glucose, cholesterol, triglyceride, albumin, total bilirubin, and alkaline phosphatase levels were 37.5 IU/L (18-132); 58 IU/L (19-132); 98 mg/dL (86-176); 217 mg/dL (169-275); 150 mg/dL (77-305); 4.5 g/dL (4.1-4.9); 0.7 mg/dL (0.1-1.4); 108 IU/L (57-330), respectively. The distribution of patients in different fibrosis stages was: 0 (n=1), 1 (n=7), 2 (n=1), 3 (n=5), 4 (n=4). Degree of steatosis was: 0 (n=0), 1(n=7), 2(n=3), 3(n=8).

Table 1 Patients' characteristics

N	18
Age, years	52 (23-73)
Male gender, n (%)	14 (78)
Body mass index	28.1 (20.1- 38.2)
Alkaline phosphatase (IU/L)	108 (57-330)
Albumin (g/dL)	4.5 (4.1-4.9)
Total bilirubin (mg/dL)	0.7 (0.1-1.4)
Cholesterol (mg/dL)	217 (169-275)
Triglycerides (mg/dL)	98 (86-176)
AST (IU/L)	37.5 (18-132)
ALT (IU/L)	58 (19-132)
Glucose (mg/dL)	98 (86-176)

N.B. : Data are presented as the median (range) unless otherwise indicated

ADC correlation with clinical variables

DWI examination was technically successful in all patients. Data processing was possible in all subjects. ADC at b value of 0-1000 s/mm² had a significant inverse correlation with age ($r=-0.66$, $P=0.002$). It was also correlated with anthropometric characters, like BMI and waist circumference ($r=-0.47$, $P=0.04$ and $r=-0.46$, $P=0.05$, respectively). Total cholesterol and AST levels were the only laboratory values that showed a relationship with ADC ($r=-0.53$, $P=0.05$ and $r=-0.58$, $P=0.01$, respectively). All these relationships were not found significant for ADC at b value of 0-500 s/mm².

ADC correlation with histological parameters

Steatosis was not associated with ADC, neither for b value of 0-500 s/mm² ($P=0.64$), or for b value of 0-1000 s/mm² ($P=0.09$). Fibrosis stage was poorly associated with ADC at b value of 0-500 s/mm² ($r=-0.30$, $P=0.27$) yet it was significantly associated with ADC at b value of 0-1000 s/mm² ($r=-0.57$, $P=0.01$). For this b value (0-1000 s/mm²) the area under ROC curve was 0.93 for fibrosis stage ≥ 3 and the optimal ADC cut-off value was 1.16×10^{-3} mm²/s by maximizing the sum of sensitivity and specificity (positive predictive value: 100%, negative predictive value: 90%)(Fig. 2, 3). Namely, no patient with fibrosis stage <3 had ADC value lower than 1.16×10^{-3} mm²/s, whereas only 1 patient with fibrosis stage ≥ 3 had ADC value greater than 1.16×10^{-3} mm²/s. Significant decrease in ADC values was seen in patients with fibrosis stage ≥ 3 versus fibrosis stage ≤ 2 , especially for b value of 0-1000 s/mm² (Table 2).

The ability to discriminate fibrosis stage ≥ 2 at b value of 0-1000 s/mm² was also very good (area under ROC curve 0.88). As the sample of patients was very similar (only one patient had fibrosis stage 2) between the groups with fibrosis stage ≥ 3 and ≥ 2 , the optimal ADC cut-off value for this group of patients was the same (1.16×10^{-3} mm²/s), but with different predictive values (positive predictive value: 100%, negative predictive value: 80%). However, the ability to diagnose

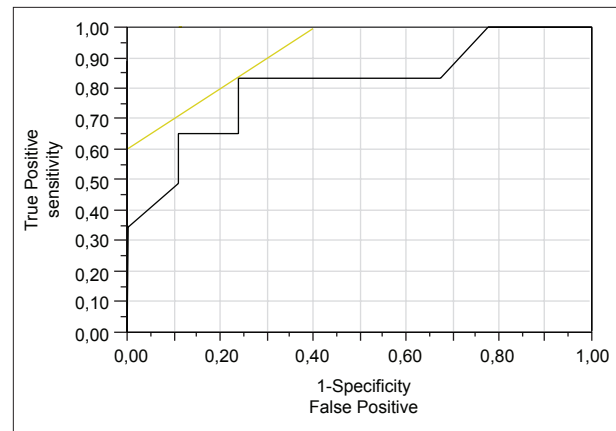


Figure 2 Receiver operating characteristics curve for fibrosis stage ≥ 3 at b value of 0-500 s/mm²

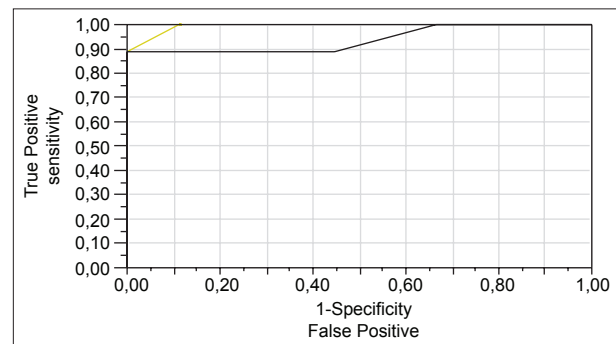


Figure 3 Receiver operating characteristics curve for fibrosis stage ≥ 3 at b value of 0-1000 s/mm²

cirrhosis (fibrosis stage 4) was poor (area under ROC curve 0.64, positive predictive value: 43%) and only exclusion of this condition could be safely predicted (negative predictive value: 91%).

Discussion

The diagnosis and treatment of patients with NAFLD depends significantly on liver fibrosis staging. Liver biopsy is still considered the "gold standard" for the assessment of liver fibrosis and is currently recommended by professional society practice guidelines. Although generally safe, this procedure is invasive and has a minor possibility of serious adverse events (hemorrhage, death)[12]. In addition, the accuracy of liver biopsy varies significantly depending on inter-observer variability and sampling error. This results in up to 30% false-negative results and underestimation of cirrhosis, especially in small (<1.5 cm) or fragmented specimens [13-16].

During the last decade a number of non invasive methods for liver fibrosis assessment have been introduced. MRI methods like MR elastography, spectroscopy and DWI are being evaluated as non invasive methods of liver fibrosis assessment. Advantages of MRI methods include the ability

to scan the whole liver to minimize sampling error, the lack of requirement for an acoustic window as in transient elastography, insensitivity in body habitus and ascites and, finally, the ability to obtain conventional MRI in the same setting.

DWI is affected by the biophysical properties of tissue cell organization (cell membranes, fibers and macromolecules), density, microstructure and microcirculation. Pathological processes which change the volume ratio or physical nature of intra- and extracellular spaces affect the diffusion of water molecules. Restricted or impeded diffusion is seen in tissues with high cellularity, e.g. tumors, abscesses, fibrosis and cytotoxic edema. Relative free or unimpeded diffusion is encountered in tissues with low cellularity or tissues with disrupted cell membranes, for example in cysts and necrotic tissues [17-20]. Low ADC values mean restricted diffusion, thus in tissues which are highly cellular. High ADC values are seen in areas with relative free diffusion, thus in tissues with low cellularity.

DWI performed with current generation scanners (1, 5 Tesla) does not appear to be reliable enough to replace liver biopsy [21]. Theoretically, the new generation 3 Tesla technology could improve hepatic ADC detection [22]. The increased signal to noise ratio inherent in the 3 Tesla scanners provides higher sensitivity in areas of restricted diffusion, while the use of parallel imaging through the reduction of TE reduces the susceptibility artifacts [23,24].

Our study showed a significant inverse correlation between liver fibrosis and ADC values taken in 3 Tesla DWI among NAFLD patients. This correlation was significantly associated with ADC at b value of 0-1000 s/mm². ADC cut-off value of 1.16×10^{-3} mm²/s was shown to predict severe fibrosis (stage ≥ 3) thus providing a potentially useful tool for the assessment of these patients. To our knowledge there are only two reports regarding liver fibrosis correlation with ADC values performed on 3 Tesla MRI scanners in patients with chronic liver disease. The first one included 37 patients with chronic viral hepatitis and 34 healthy volunteers. The authors reported significant inverse correlation of ADC values with liver fibrosis with a b factor of 1000 s/mm² [25]. The second one included 55 patients with chronic liver disease who had undergone DWI using 8 b-values at 3 Tesla. Significant correlation of ADC values with hepatic fibrosis was reported. Higher ADC values were seen in fibrosis stage F ≤ 1 compared to fibrosis stage F=4 [26].

Conflicting results regarding liver fibrosis and DWI in 1.5 Tesla scanners are reported. Taouli *et al* [7] reported significant inverse correlation of ADC and liver fibrosis in patients with chronic liver disease with AUC of 0.896 and cut off value of 1.03×10^{-3} mm²/s at 0-1,000 b value for fibrosis stage ≥ 3 . Koinuma *et al* [27] evaluated a large population of patients (n=163), 31 of whom underwent liver biopsy and found significant inverse correlation between hepatic ADC and fibrosis stage in lower b value (128 s/mm²). Sandrasegaran *et al* [21] reported significantly lower ADCs in cirrhotic livers compared with nonfibrotic livers but ADC values were not useful for differentiating patients with fibrosis stage ≥ 2 from those with a lower degree of fibrosis. Lewin *et al* [28] compared DWI in 54 hepatitis C patients and 20 healthy volunteers with

FibroScan and FibroTest. They found that DWI was comparable to these tests in detecting severe fibrosis but they also reported significant overlap of ADC values between patients with mild and moderate fibrosis. Bakan *et al* [29] reported that lower ADC values were associated with higher fibrosis stages in 34 patients with chronic liver disease. Bonekamp *et al* [30] found that liver ADC values were inversely correlated with fibrosis stage. AUROCs of 0.79, 0.77, 0.77 and 0.79 were obtained for fibrosis stages 1,2,3, and 4 respectively.

This study also shows that ADC at b value at 0-1,000 s/mm² has statistically significant inverse correlation with liver fibrosis compared to b value at 0-500 s/mm². The sensitivity of a DWI sequence is characterized by its b value. The higher the b value, the more sensitive the sequence is to diffusion effects [21,31]. Boulanger *et al* [32] used DWI at b values of 50-250 s/mm² in 18 chronic hepatitis C patients and 10 control subjects. They found no significant difference between the two groups. Interestingly the ADCs of patients with hepatitis C were even higher than those of controls. It is possible that differences between fibrotic and nonfibrotic liver cannot be detected at small b values (<300 s/mm²), which can increase the amount of perfusion contamination in ADC measurement [31,33]. In a recent study including 24 patients with chronic liver disease and 22 healthy volunteers, ADC values at b value of 750 s/mm² or greater showed superior correlation with liver fibrosis compared to lower b values [34]. On the other hand, some researchers believe that there may be an advantage to calculating ADC values using an intermediate b value compared to a higher b value [35]. According to our results, we believe that 3 Tesla DWI at b value of 1,000 s/mm² provides a relative advantage for liver fibrosis assessment compared to 1.5 Tesla technology scanners.

We acknowledge some limitations of our study. First, this is a pilot study where we report our preliminary experience with a small number of patients. Also, DWI is more expensive than other non invasive methods of liver fibrosis assessment with comparable effectiveness. In addition, MRE was shown to be superior in predicting liver fibrosis as compared with DWI in a recently published meta-analysis [36]. However, all studies included in this analysis were performed with 1.5 Tesla scanners. As it was recently pointed out, the strength of the magnetic field that the scanner uses plays a vital role in interpreting the results [37].

In conclusion, our findings suggest that 3 Tesla DWI can possibly predict the presence of advanced (≥ 3) fibrosis in patients with NAFLD especially when the b value is 0-1000 s/mm². Future work is needed to assess a larger number

Table 2 Comparison of liver apparent diffusion coefficient (ADC) (value $\times 10^{-3}$ mm²/s) for fibrosis stage ≤ 2 and ≥ 3 (n=18)

Fibrosis stage	b value 0-500	b value 0-1000
≤ 2	1.61 \pm 0.16	1.30 \pm 0.08
≥ 3	1.39 \pm 0.18	1.06 \pm 0.14
P	0.05	0.001

N.B. Liver ADC decrease is statistically significant in patients with advanced fibrosis at b values of 1000 s/mm²

Summary Box

What is already known:

- Diffusion-weighted imaging (DWI) is being evaluated increasingly over the last decade as an alternative to liver biopsy for staging liver fibrosis
- Conflicting results regarding DWI's efficacy in predicting liver fibrosis are reported
- The majority of reports made until now were performed with 1.5 Tesla scanners
- Only two reports with 3 Tesla scanners are available regarding mostly patients with chronic viral hepatitis

What the new findings are:

- The present study was performed in a 3 Tesla magnetic resonance imaging scanner including patients with NAFLD
- The b value of 0-1000 s/mm² is shown superior for liver fibrosis staging
- This is the first study in a Greek population

of patients with NAFLD and to correlate 3 Tesla DWI findings with liver fibrosis. These new technology scanners may provide a useful tool for the treatment and follow up of this subset of patients.

References

1. Browning JD, Szczepaniak LS, Dobbins R, et al. Prevalence of hepatic steatosis in an urban population in the United States: impact of ethnicity. *Hepatology* 2004;**40**:1387-1395.
2. Bedogni G, Miglioli L, Masutti F, et al. Prevalence of and risk factors for nonalcoholic fatty liver disease: the Dionysos nutrition and liver study. *Hepatology* 2005;**42**:44-52.
3. Machado M, Marques-Vidal P, Cortez-Pinto H. Hepatic histology in obese patients undergoing bariatric surgery. *J Hepatol* 2006;**45**:600-606.
4. Neuschwander-Tetri BA, Caldwell SH. Nonalcoholic steatohepatitis: summary of an AASLD Single Topic Conference. *Hepatology* 2003;**37**:1202-1219.
5. Yin M, Talwalkar JA, Glaser KJ, et al. Assessment of hepatic fibrosis with magnetic resonance elastography. *Clin Gastroenterol Hepatol* 2007;**5**:1207-1213.
6. Taouli B, Ehman RL, Reeder SB. Advanced MRI Methods for Assessment of Chronic Liver Disease. *AJR* 2009;**193**:14-27.
7. Taouli B, Tolia A, Losada M, et al. Diffusion-Weighted MRI for Quantification of Liver Fibrosis: Preliminary Experience. *AJR* 2007;**189**:799-806.
8. Namimoto T, Yamashita Y, Sumi S, et al. Focal liver masses: characterization with diffusion-weighted echo-planar MR imaging. *Radiology* 1997;**204**:739-744.
9. Ichikawa T, Haradome H, Hachiya J, et al. Diffusion-weighted MR imaging with a single-shot echoplanar sequence: detection and characterization of focal hepatic lesions. *AJR* 1998;**170**:397-402.
10. Amano Y, Kumazaki T, Ishihara M. Single-shot diffusion-weighted echo-planar imaging of normal and cirrhotic livers using a phased-array multicoil. *Acta Radiol* 1998;**39**:440-442.
11. Kleiner DE, Brunt EM, Van Natta M, et al. Design and validation of a histological scoring system for nonalcoholic fatty liver disease. *Hepatology* 2005;**41**:1313-1321.
12. Bravoo AA, Sheth S, Chopra S. Liver biopsy. *N Engl J Med* 2001;**344**:495-500.
13. Castéra L, Nègre I, Samii K, et al. Pain experienced during percutaneous liver biopsy. *Hepatology* 1999;**30**:1529-1530.
14. Colloredo G, Guido M, Sonzogni A, et al. Impact of liver biopsy size on histological evaluation of chronic viral hepatitis: the smaller the sample, the milder the disease. *J Hepatol* 2003;**39**:239-244.
15. Regev A, Berho M, Jeffers LJ, et al. Sampling error and intraobserver variation in liver biopsy in patients with chronic HCV infection. *Am J Gastroenterol* 2002;**97**:2614-2618.
16. Siddique I, El-Naga HA, Madda JP, et al. Sampling variability on percutaneous liver biopsy in patients with chronic hepatitis C virus infection. *Scand J Gastroenterol* 2003;**38**:427-432.
17. Kele PG, van der Jagt EJ. Diffusion weighted imaging in the liver. *World J Gastroenterol* 2010;**16**:1567-1576.
18. Charles-Edwards EM, deSouza NM. Diffusion-weighted magnetic resonance imaging and its application to cancer. *Cancer Imaging* 2006;**6**:135-143.
19. Thoeny HC, De Keyzer F. Extracranial applications of diffusion-weighted magnetic resonance imaging. *Eur Radiol* 2007;**17**:1385-1393.
20. Kwee TC, Takahara T, Ochiai R, et al. Diffusion-weighted whole-body imaging with background body signal suppression (DWIBS): features and potential applications in oncology. *Eur Radiol* 2008;**18**:1937-1952.
21. Sandrasegaran K, Akisik FM, Lin C, et al. Value of Diffusion-Weighted MRI for Assessing Liver Fibrosis and Cirrhosis. *AJR* 2009;**193**:1556-1560.
22. Taouli B, Martin AJ, Qayyum A, et al. Parallel imaging and diffusion tensor imaging for diffusion-weighted MRI of the liver: preliminary experience in healthy volunteers. *AJR* 2004;**183**:677-680.
23. Chang K, Kamel I, Macura K, Bluemke D. 3.0-T MR Imaging of the Abdomen: Comparison with 1.5 T. *Radiographics* 2008;**28**:1983-1998.
24. Erturk SM, Alberich-Bayarri A, Hermann KA, Martin-Bonnati L, Ros PR. Use of 3.0-T MR imaging for evaluation of the abdomen. *Radiographics* 2009;**29**:1547-1563.
25. Tosun M, Inan N, Sarisoy HT, et al. Diagnostic performance of conventional diffusion weighted imaging and diffusion tensor imaging for the liver fibrosis and inflammation. *Eur J Radiol* 2013;**82**:203-207.
26. Yoon JH, Lee JM, Baek JH, et al. Evaluation of hepatic fibrosis using intravoxel incoherent motion in diffusion-weighted liver MRI. *J Comput Assist Tomogr* 2014;**38**:110-116.
27. Koinuma M, Ohashi I, Hanafusa K, et al. Apparent diffusion coefficient measurements with diffusion-weighted magnetic resonance imaging for evaluation of hepatic fibrosis. *J Magn Reson Imaging* 2005;**22**:80-85.
28. Lewin M, Poujol-Robert A, Boelle PY, et al. Diffusion-weighted magnetic resonance imaging for the assessment of fibrosis in chronic hepatitis C. *Hepatology* 2007;**46**:658-665.
29. Bakan AA, Inci E, Bakan S, Gokturk S, Cimilli T. Utility of diffusion-weighted imaging in the evaluation of liver fibrosis. *Eur Radiol* 2012;**22**:682-687.
30. Bonekamp S, Torbenson MS, Kamel IR. Diffusion-weighted magnetic resonance imaging for the staging of liver fibrosis. *J Clin Gastroenterol* 2011;**45**:885-892.
31. Woodhams, Ramadan S, Stanwell P, et al. Diffusion-weighted

- Imaging of the breast: Principles and clinical applications. *Radiographics* 2011;**31**:1059-1084.
32. Boulanger Y, Amara M, Lepanto L, et al. Diffusion weighted MR imaging of the liver of hepatitis C patients. *NMR Biomed* 2003;**16**:132-136.
 33. Yamada I, Aung W, Himeno Y, et al. Diffusion coefficients in abdominal organs and hepatic lesions: evaluation with intravoxel incoherent motion echo-planar MR imaging. *Radiology* 1999;**210**:617-623.
 34. Ozkurt H, Keskiner F, Karatag O, Alkim C, Erturk SM, Basak M. Diffusion weighted MRI for hepatic fibrosis: impact of b-value. *Iran J Radiol* 2014;**11**:e3555.
 35. Girometti R, Furlan A, Esposito G, et al. Relevance of b-values in evaluating liver fibrosis: a study in healthy and cirrhotic subjects using two singleshot spin-echo echo-planar diffusion-weighted sequences. *J Magn Reson Imaging* 2008;**28**:411-419.
 36. Wang QB, Zhu H, Liu HL, et al. Performance of magnetic resonance elastography and diffusion-weighted imaging for the staging of hepatic fibrosis: A meta-analysis. *Hepatology* 2012;**56**:239-47.
 37. Papalavrentios L, Sinakos E, Chourmouzi D, et al. 3 Tesla diffusion-weighted MRI for assessing liver fibrosis in nonalcoholic fatty liver disease. *Hepatology* 2013;**58**:449-450.