

Cardiac dysfunction in cirrhotic portal hypertension with or without ascites

Sunil Dadhich^a, Amitava Goswami^a, Vinit Kumar Jain^b, Ankur Gahlot^c, Ganaraj Kulamarva^a, Narendra Bhargava^a

Dr Sampurnanand Medical College, Jodhpur, India

Abstract

Background Alteration of cardiovascular functions in patients with liver cirrhosis has been described and it correlates with severity of hepatic failure. But cardiac functions by conventional 2-dimensional (2-D) echocardiography has limitations. The aim of the study was to evaluate cardiac systolic and diastolic functions in liver cirrhosis patients with or without ascites by tissue Doppler imaging and conventional 2-D- echocardiography.

Methods A cross sectional case control study of sixty patients. Twenty subjects grouped as healthy controls, pre-ascitic cirrhosis and cirrhosis with ascites were enrolled. Cardiac evaluation was done by both conventional Doppler and tissue Doppler echocardiography.

Results Cirrhosis with portal hypertension is associated with increased heart rate, ejection fraction and mean peak systolic velocity, while mean arterial pressure is decreased. All cardiac chamber dilation occurs and is mostly seen in the left atrium. Ratio of early diastolic annular velocity to peak early diastolic annular wave velocity (E/e') was the most significant marker for diastolic dysfunction. E/e' ratio was 7.76 ± 0.40 , 12.55 ± 1.73 and 11.4 ± 1.19 in healthy controls, pre ascitic cirrhosis and ascitic cirrhosis respectively ($P < 0.0001$). Overall Type I and II Left ventricular diastolic dysfunction was present in 70% cirrhotic patient with or without ascites, while there were no cases of Type III (Severe) diastolic dysfunction.

Conclusion Left ventricular diastolic dysfunction is commonly associated with advancement of hepatic dysfunction while systolic function is maintained till advanced hepatic failure. Peak early diastolic wave velocity, deceleration time and E/e' ratio for left ventricular diastolic dysfunction are accurately assessed by pulsed tissue Doppler imaging.

Keywords Tissue Doppler imaging, peak systolic velocity, early diastolic velocity, late diastolic velocity, peak early diastolic wave velocity

Ann Gastroenterol 2014; 27(3): 1-6

Introduction

Cardiomyopathy is derived from the Greek roots: cardia (heart), mys (muscle) pátheia/páthesis (disease), that is, it is a condition affecting the heart muscles. Historically, liver cirrhosis has not been associated with any cardiac abnormalities, despite the fact that a hyperdynamic circulation has been described in patients with cirrhosis

more than 50 years ago. Kowalski and Abelmann noted a higher resting cardiac output and decreased systemic vascular resistance in patients with cirrhosis [1]. However these abnormalities were initially thought to be a manifestation of latent alcoholic cardiomyopathy. But later in the mid-1980s, studies in non-alcoholic patients and in experimental animal models showed a similar pattern of blunted cardiac contractile responsiveness [2-4]. Thus these cardiovascular changes are now termed 'cirrhotic cardiomyopathy' [5-8]. The main clinical features of cirrhotic cardiomyopathy include baseline increased cardiac output, attenuated systolic contraction or diastolic relaxation in response to physiologic, pharmacologic and surgical stress, and electrical conductance abnormalities (prolonged QT interval). In the majority of cases, diastolic dysfunction precedes systolic dysfunction, which tends to manifest only under conditions of stress. Cardiac response to physical exercise in cirrhotic patients is blunted, with subnormal responses in echocardiographic ejection

Departments of ^aGastroenterology (Sunil Dadhich, Amitava Goswami, Ganaraj Kulamarva, Narendra Bhargava); ^bCardiology (Vinit Kumar Jain); ^cMedicine (Ankur Gahlot), Dr Sampurnanand Medical College, Jodhpur

Conflict of Interest: None

Correspondence to: Amitava Goswami, Department of Gastroenterology, S.N.M.C. Jodhpur 352001, Rajasthan, India, Tel.: +087699 47345, e-mail: amitavagoswami77@gmail.com

Received 2 December 2013; accepted 3 March 2014

fraction and contraction time. Moreover, both ventricular systolic and diastolic function are impaired in cirrhosis [6,7,9,10]. Cazzaniga and colleagues demonstrated that the echocardiography measurement of early diastolic and late diastolic annual velocity ratio (E/A), an indicator of diastolic dysfunction measured at 4 weeks after tranjugular intrahepatic portosystemic shunt (TIPS) insertion, was the single independent predictor of survival following this procedure [11]. However conventional Doppler echocardiography (E/A ratio) has limitations and it rarely differentiates normal from pseudo normal patterns. Tissue Doppler Imaging (TDI) is the most sensitive equipment for assessing left ventricular filling dynamics [12]. So, the current study was conducted to evaluate cardiac systolic and diastolic functions in liver cirrhosis patients with portal hypertension by conventional Doppler echocardiography and TDI.

Patients and methods

A total of sixty subjects were enrolled in this cross sectional case control study, conducted at the Department of Gastroenterology Dr Sampurnanand Medical College, Jodhpur over a period of 6 months (February-July, 2013). The study was approved by the ethics committee of the Medical College. After written consent, subjects were counseled and explained about the objectives of the study by a qualified medical doctor. Detailed personal history was taken using a standard questionnaire.

Evaluation of cardiac systolic and diastolic functions in liver cirrhosis patients with portal hypertension conventional was done by conventional Doppler echocardiography and TDI. Inclusion criteria comprised: 1) cirrhotic patients with or without ascites, diagnosis of cirrhosis was based on histopathological evidence (liver biopsy) or unequivocal clinical grounds (chronic liver disease stigmata, jaundice, ascites, esophageal varices), impaired liver function tests and ultrasonographic features consistent with cirrhosis (diffuse alteration and nodular transformation of liver parenchyma, and signs of portal hypertension); and 2) healthy controls. Exclusion criteria comprised: 1) history or clinical evidence of cardiovascular disease; 2) major lung disease; 3) diabetes mellitus; 4) terminal liver failure; 5) tense ascites; 6) major arrhythmias; 7) severe anemia (Hb <7 gm/dL); 8) hepatic encephalopathy; 9) renal failure (serum creatinine >1.5 mg/dL); 10) recent alcohol consumption (<6 months); 11) drugs which may affect the parameters under study as sympathomimetics, nitrates or other anti-hypertensive in past 4 weeks; 12) history or sphygmomanometer evidence of hypertension according to JNC 7 criteria [13].

Echocardiography devices

Conventional two-dimensional (2-D) Doppler echocardiography and pulsed TDI was done with GE-Ving Med System 5 echocardiographic machine (GE-Ving Med sound AB, Horten, Norway). The procedure was done with

a 2.5 MHz multiphase array probe in standard parasternal and apical views according to the recommendations of the American Society of Echocardiography (ASE)[14]. The ejection fraction was obtained using a modified biplane Simpson's method from apical two and four chamber view. Measurements were made from three consecutive beats and the average of three beats was used for analysis. Doppler recordings of diastolic mitral flow was obtained by using apical four-chamber view and measurements were made by taking an average of two consecutive beats. Early [Em] and late [Am] diastolic velocities (trans mitral); Early [Er] and late [Ar] diastolic velocities (trans tricuspid) were obtained. E/A ratios were calculated for both mitral and tricuspid annulus. Pulsed tissue Doppler (M-mode) displays the direction, timing and synchronicity of the motion of myocardium in the segment selected by the scan line. This technique was used to quantify the segmental movement of the ventricular myocardium as well as diastolic and systolic functions [15].

The mitral peak systolic annular velocity (Sm), early diastolic (E_{tm}) and late diastolic annular velocity (A_{tm}) was measured at four different sites at mitral annulus (anterior, inferior, lateral and septal). An average of all the four velocities was taken as mean velocity at mitral annulus. Tricuspid peak systolic annular velocity (St), early diastolic annular velocity (E_{tr}) and late diastolic velocity annular velocity (A_{tr}) were measured at two different sites (lateral and septal). The average of these two velocities was taken as the mean velocity at tricuspid annulus. Recordings for mitral inflow with Valsalva maneuver were not performed. Other parameters were also measured: left atrial volume (LAV), isovolumetric relaxation time (IVRT) and deceleration time (DT). Peak early diastolic annular velocity (e') was measured at septal and lateral mitral annulus sites and the average value was calculated. E/e' ratio was calculated. VJ who performed and interpreted the echocardiograms had no knowledge of the clinical and laboratory status of the patient.

Left ventricular diastolic dysfunction (LVDD) was graded according to the ASE guidelines (2009)[14]. LVDD was defined as: *Normal or Grade 0*: LAV <34 ml/m², E/A >1 e' >8 cm/sec, E/e' <8; *Mild or Grade I (Impaired relaxation pattern)*: e' <8 cm/sec, E/e' ratio <8, E/A ratio <0.8 and DT >200 ms; *Moderate or Grade II (Pseudo normal)*: e' <8 cm/sec, E/e' 9-15, E/A ratio 0.8-1.5, DT 160-200 ms and *Severe or Grade III (Restrictive filling)*: e' <8 cm/sec, E/e' ratio >15, E/A ratio >2 and DT <160 ms.

Statistical analysis

Parametric data are expressed as mean values ± standard deviation (SD) and categorical variables as percentages. The Chi-square test or Fischer's exact was used for the comparison of dichotomous variables and the Student's *t* test for continuous variables. ANOVA one-way was used to calculate P value in comparisons of more than two continuous variables. A P value

<0.05 was considered statistically significant. All data were analyzed with an SAS 8.0 statistical package.

Results

The present study was conducted in sixty subjects and consisted of three groups of 20 patients each of healthy controls, cirrhosis without ascites and cirrhosis with ascites respectively. All the cases were carefully selected after ruling out exclusion criteria while the presence or absence of ascites was determined with abdominal ultrasonography. The twenty healthy controls were the resident physician and doctors. The pre-ascitic cirrhosis group and the ascitic cirrhotic groups were comparable, except for decreased serum albumin and advanced Child Pugh Turcotte score in the later group (Table 1). The patients selected in the present study had liver cirrhosis of varied etiology, while alcoholic liver disease primary comprised 25% of cases and all of them had abstained from alcohol for more than 6 months. Twenty three patients were already receiving non selective β -blocker (propranolol) for management of portal hypertension and most of the patients had ascites (P=0.03).

Morphological parameters

The cardinal cardiac parameters such as heart rate, mean arterial pressure, ejection fraction and the individual cardiac chamber size were compared between the three groups. There was a significant rise in heart rate and ejection fraction (P value 0.05 and 0.005 respectively) in patients with ascitic cirrhosis as compared to other groups; although no significant fall in mean atrial pressure was seen in cirrhotic patients with ascites (P value 0.14).

Cardiac chamber size was assessed in all the four chambers with the conventional 2-D echocardiography (Fig. 1). Echocardiography was performed and interpreted in accordance with guidelines set by ASE [16]. All cardiac chambers were seen to be significantly enlarged in cirrhotic patients with ascites (Table 2). Left atrial enlargement was most eminent among the cardiac chamber dimensions (P<0.0001).

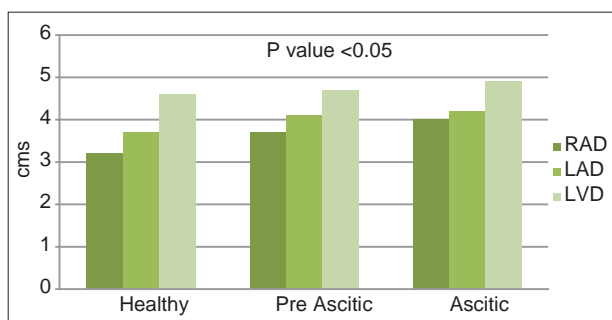


Figure 1 Cardiac chamber dimensions in controls, pre-ascitic and ascitic cirrhosis

Conventional 2-D echocardiography

The diastolic parameters evaluated were the early diastolic velocity (E velocity) and the late diastolic velocity (A velocity) in both the mitral and tricuspid annulus. Although an increase in peak systolic velocity (Sm) at both mitral and tricuspid annulus was noted among cirrhotic patients with or without ascites as compared to healthy controls, it was not significant statistically (p value 0.70 and 0.97 respectively). Similarly no significant fall in E/A ratio at both mitral and tricuspid annulus were noted in all the three groups (P value 0.57 and 0.31 respectively) (Table 3).

Table 1 Baseline characteristics

Variables (n=60)	Healthy controls (n=20)	Pre-ascitic cirrhosis (n=20)	Ascitic cirrhosis (n=20)	P value*
Age (yrs)				0.27
Mean±SD	40.5±6.2	41.8±5.9	39.9±8.04	
Range	(31-50)	(32-50)	(32-56)	
AST (U/dL)				0.08
Mean±SD	27±5	76.4±29.5	56.4±31.3	
Range	(22-34)	(18-110)	(18-102)	
ALT (U/dL)				0.13
Mean±SD	25±6	66.2±31	51±28.05	
Range	(17-33)	(18-102)	(22-102)	
Albumin (g/dL)				0.009
Mean±SD	4.3±0.4	3.18±0.2	2.84±0.35	
Range	(3.5-4.8)	(2.9-3.6)	(2.4-3.5)	
Bilirubin (mg/dL)				0.39
Mean±SD	0.9±0.2	2.51±0.82	2.55±1.45	
Range	(0.3-1.1)	(0.8-3.6)	(1-5)	
INR				0.05
Mean±SD	1±0.05	1.55±0.3	1.87±0.49	
Range	(0.9-1.1)	(1.1-1.9)	(1.2-3.1)	
CPT score (Mean±SD)	-	7.5±1.08	9.4±2.11	0.06
		(6-9)	(6-13)	0.05
A (5-6)		4 (20)	0 (0)	0.95
B (7-9)		16 (80)	6 (30)	0.007
C (10-15)		0 (0)	14 (70)	
Etiology of cirrhosis				
Alcohol	-	4 (20)	6 (30)	0.17
HBV		10 (50)	6 (30)	0.47
HCV		4 (20)	6 (30)	0.17
NAFLD		2 (10)	2 (10)	0.23
Beta blockers	-	8 (40)	15 (60)	0.03
Non selective (Propranolol)				
Left ventricular diastolic dysfunction (LVDD)†				0.09
Stage 0 (Normal)	0 (0)	12 (60)	16 (80)	0.09
Stage I (Impaired relaxation)	20 (100)	8 (40)	4 (20)	0.15
Stage II (Pseudo normal)	0 (0)	4 (20)	7 (35)	0.38
Stage III (Restrictive filling)	0 (0)	8 (40)	9 (45)	

*P value between pre-ascitic and ascitic cirrhosis cases; †Tissue doppler imaging echocardiography classification of left ventricular diastolic dysfunction[14],

CPT, Child Pugh Turcotte score; NAFLD, Non-alcoholic fatty liver disease; HBV, Hepatitis B virus; HCV, Hepatitis C virus; AST, Aspartate transaminase; ALT, Alanine transaminase; SD, Standard deviation

TDI

The left ventricular diastolic dysfunction was assessed using the LAV, E/A ratio, e' value, E/e' ratio and DT[14].

Overall LVDD was diagnosed in 28/40 (70%) of cirrhotic patients. LVDD was seen as follows healthy controls (0%), pre-ascitic cirrhosis (60%) and ascitic cirrhosis (80%). Eleven patients had Stage I (impaired relaxation) LVDD, while 17 had Stage II (pseudo normal) LVDD (Fig. 2). None of the patients in the study group had Stage III or severe restrictive type LVDD. Most of the cirrhotic patients with ascites had LVDD as compared to cirrhotic patients without ascites but was statistically insignificant (P=0.09). E/e' ratio was the most significantly elevated in the cirrhotic patients with ascites as compared to other groups (P<0.0001), whereas there was no significant fall in E/A ratio (P=0.22).

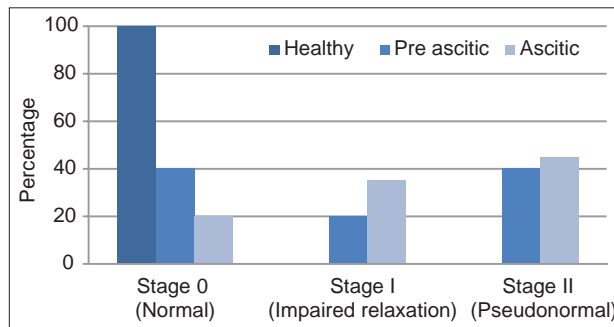


Figure 2 Left ventricular diastolic dysfunction in controls, pre-ascitic and ascitic cirrhosis

Table 2 Morphological parameters and cardiac chamber volume measurements in control, pre-ascitic and ascitic cirrhotic cases

Variables n=60 (%)	Healthy controls n=20 (%)	Pre-ascitic cirrhosis n=20 (%)	Ascitic cirrhosis n=20 (%)	P value†
HR (beats/min) Range	78.35±6.05 (71-91)	83.3±6.75 (70-90)	90.2±3.85 (82-96)	0.05
MAP (mm of hg) Range	89.1±3.97 (82-95)	85.8±2.62 (83-92)	83.5±2.83 (79-89)	0.14
EF (%) Range	67.95±2.56 (65-71)	70±3.62 (65-75)	71.1±1.66 (69-74)	0.005 ^b
RAD (cm) Range	3.2±0.17 (2.85-3.36)	3.7±0.24 (3.24-4.2)	3.99±0.33 (3.6-4.8)	0.02 ^a
LAD (cm) Range	3.75±0.12 (3.53-4)	4.11±0.47 (3.76-5.37)	4.22±0.38 (3.72-5.1)	<0.0001 ^b
RVD (cm) Range	1.59±0.2 (1.11-1.94)	1.86±0.09 (1.64-1.96)	2.02±0.11 (1.84-2.2)	0.001 ^b
LVD (cm) Range	4.59±0.19 (4.08-4.83)	4.73±0.2 (4.4-5)	4.89±0.35 (3.94-5.11)	0.01 ^a

†P value was calculated by ANOVA one-way to compare between the three groups; ^aP value <0.05, ^bP value <0.01

HR, Heart rate; MAP, Mean arterial pressure; EF, Ejection fraction; RAD, Right atrial dimension; LAD, Left atrial dimension; RVD, Right ventricular dimension; LVD, Left ventricular dimension

Discussion

Our study shows cirrhotic patients with or without ascites has both morphological and functional cardiac dysfunction. Cardiac dimension is enlarged in all the four chambers with increase in ejection fraction in cirrhotic patients with ascites. Type I and II Left ventricular diastolic dysfunction was present in seventy percent of cirrhotic patient with or without ascites. TDI with assessment of LAV, e', E/e' and DT can classify

Table 3 Cardiac dimensions in controls and patients with cirrhosis (measured by conventional 2 dimensional (2D)-pulsed and tissue Doppler echocardiography at mitral and tricuspid annulus)

n (60) Mean ± SD	Healthy controls (n=20)	Pre-ascitic cirrhosis (n=20)	Ascitic cirrhosis (n=20)	P value
EF (%)	67.95±2.56 (65-72)	70±3.62 (65-76)	71.1±1.66 (69-74)	0.005 ^b
Conventional 2D-pulsed doppler echocardiography				
Mitral annulus (cm/sec)				
Sm	10.54±1.27 (7.8-11.8)	11.6±1.24 (9.2-12.4)	12.45±1.06 (9.6-12.9)	0.70
Em/Am ratio	1.13±0.11 (0.97-1.37)	0.99±0.14 (0.77-1.07)	0.90±0.12 (0.71-0.97)	0.57
Tricuspid annulus (cm/sec)				
Sm	7.77±0.84 (6.2-9.6)	8.21±0.80 (7.2-10.3)	8.89±0.84 (8.1-10.5)	0.97
Er/Ar ratio	1.12±0.10 (0.97-1.39)	1.01±0.14 (0.62-1.16)	0.91±0.11 (0.56-0.96)	0.31
Tissue doppler echocardiography (TDI)				
Mitral annulus (cm/sec)				
LAV (ml/m ²)	20.9±3.5 (16.4-27.1)	34.8±2.9 (29.8-38.1)	36.5±2.3 (34.2-41.1)	0.20
E tm/Atm ratio	1.11±0.12 (0.97-1.37)	0.96±0.08 (0.77-1.07)	0.84±0.10 (0.71-0.97)	0.22
e' (cm/sec)	11.55±0.82 (10.1-12.9)	7.48±0.48 (6.9-8.2)	7.49±0.36 (6.9-8.2)	0.001 ^b
E/e' ratio	7.76±0.40 (7.16-8.3)	12.55±1.73 (10.04-14.65)	11.4±1.19 (9.5-12.9)	<0.0001 ^b
DT (msec)	173.5±8.36 (161-194)	209.8±11.15 (190-224)	201.1±22.38 (168-234)	<0.0001 ^b
Tricuspid annulus (cm/sec)				
E tr/Atr ratio	1.09±0.12 (0.97-1.39)	0.94±0.14 (0.62-1.16)	0.83±0.12 (0.56-0.96)	0.73

^aP value <0.05, ^bP value <0.01, P value was calculated by ANOVA one-way to compare between the three groups

Sm, peak systolic velocity; Em, early diastolic velocity at mitral annulus (measured by conventional 2D doppler); Am, late diastolic velocity at mitral annulus (conventional 2D doppler); Er, early diastolic velocity at tricuspid annulus (conventional 2D doppler); Ar, late diastolic velocity at tricuspid annulus (conventional 2D doppler); E tm, early diastolic velocity at mitral annulus (TDI); A tm, late diastolic velocity at mitral annulus (measured by TDI); E tr, early diastolic velocity at tricuspid annulus (TDI); A tr, late diastolic velocity at tricuspid annulus (TDI); LAV, left atrial volume; e', early peak diastolic annular velocity; DT, deceleration time

the LVDD. While the left ventricular systolic function was preserved in all the studied patients.

Diastolic dysfunction appears to be more prevalent in cirrhotic patients, indeed some authorities contend that some degree of diastolic dysfunction is present in virtually every patients with cirrhosis [17,18]. In most of the studies performed in the recent past, diagnosis of LVDD was based on E/A ratio <1 using 2-D Doppler echocardiography. Valeriano *et al* also found a similar lower mean E/A ratio in both left and right ventricle in ascitic subgroup than in non-ascitic subgroup [19]. Pozzi *et al* showed that removal of ascitic fluid by rapid total paracentesis reduced the A wave velocity and increased the E/A ratio to the values similar to those of cirrhotic patients without ascites, but still abnormal as compared to healthy controls [20].

However, E/A ratio have several limitations as it is strongly dependent on preload and often requires age correction [14,21]. Unlike transmitral valve Doppler flow, TDI directly measures the velocity of myocardial displacement as the LV expands in the diastole and therefore is independent of volume status and left atrial pressure. The ASE has included TDI parameters in the definition of LVDD. A recent study by Ruiz del Arbol *et al* showed LVDD in 37/80 (46.2%) with TDI in cirrhotic patients. They also found LVDD occurs simultaneously with other changes in cardiac structure and function and is associated with an impairment of effective arterial blood volume. LVDD was a sensitive marker of advanced cirrhosis, type 1 hepatorenal syndrome development, and mortality [22].

Our study shows left ventricular diastolic dysfunction is present in most of the cirrhotic patients which was detected by TDI in 70% of cases. This rate is somewhat more than the 50-60% found in recent study conducted by both TDI and Doppler echocardiography [22,23]. Twenty three patients in the current study were already on β -blockers which could have added or aggravated the diastolic dysfunction. Another limitation of the current study was that Valsalva maneuver was not performed during mitral valve flow analysis by TDI, this might have overstaged the diastolic dysfunctions in a few of the cases.

The mean peak systolic velocities in both the mitral and tricuspid annulus were comparable in all the three groups, whereas the ejection fraction which was significantly elevated in patients with decompensated cirrhosis as compared to health controls and compensated cirrhosis (P value 0.005). Various studies have shown stroke volume and contractile indices are typically normal or even increased at rest. However, under stressful stimuli such as exercise, renal failure, haemorrhage or drug infusions, cirrhotic patients may show an attenuated systolic function compared to healthy controls [24-26]. In our study systolic dysfunction was not seen, which probably reflects the exclusion criteria used in the current study; as patients with renal failure, tense or refractory ascites and terminal liver failure patient were excluded.

Lengeyl *et al* studied ninety six patients of various etiologies, and diastolic dysfunction was assessed by TDI and conventional echocardiography. They found that about 1/3rd of the patients could be classified into a diastolic dysfunction pattern only by using TDI [27]. In our study LVDD (Type I and II) was seen in eighty percent of cirrhotic patients with ascites as compared to

Summary Box

What is already known:

- Cirrhotic cardiomyopathy occurs in cirrhosis of varied etiology
- Biventricular diastolic and systolic dysfunction is common in decompensated cirrhosis
- Conventional echocardiography has limitations in estimating diastolic dysfunction accurately by E/A wave velocity ratio

What the new findings are:

- Left ventricular diastolic dysfunction of decompensated cirrhosis occurs in two thirds of patients
- Systolic cardiac function in cirrhosis is preserved in absence of renal failure or refractory ascites
- Tissue Doppler imaging echocardiography is the best modality to assess diastolic dysfunction

sixty percent of cirrhotic patients without ascites (p value 0.09). Parameters regarding left ventricular systolic performance were within normal range. Further studies are required to assess the prognostic impact of left ventricular diastolic dysfunction in patients with cirrhosis and the cut off parameter to taper or abandon beta blocker. In conclusion, left ventricular diastolic dysfunction is commonly associated with advancement of hepatic dysfunction while systolic function is maintained till advanced hepatic failure. Peak early diastolic wave velocity, deceleration time and E/e' ratio for diastolic dysfunction are accurately assessed by pulsed TDI.

References

1. Kowalski HJ, Abelmann WH. The cardiac output at rest in Laennec cirrhosis. *J Clin Invest* 1953;32:1025-1033.
2. Caramelo C, Fernandez-Munoz D, Santos JC, et al. Effect of volume expansion on hemodynamics, capillary permeability and renal function in conscious, cirrhotic rats. *Hepatology* 1986;6:129-134.
3. Lee SS, Marty J, Mantz J, Samain E, Braillon A, Lebrech D. Desensitization of myocardial β -adrenergic receptors in cirrhotic rats. *Hepatology* 1990;12:481-485.
4. Ingles AC, Hernandez I, Garcia-Estan J, Quesada T, Carbonell LF. Limited cardiac preload reserve in conscious cirrhotic rats. *Am J Physiol* 1991;260:H1912-H1917.
5. Lee SS. Cardiac abnormalities in liver cirrhosis. *West J Med* 1989;151:530-535.
6. Ma Z, Lee SS. Cirrhotic cardiomyopathy: getting to the heart of the matter. *Hepatology* 1996;24:451-459.
7. Liu H, Lee SS. Cardiopulmonary dysfunction in cirrhosis. *J Gastroenterol Hepatol* 1999;14:600-608.
8. Myers RP, Lee SS. Cirrhotic cardiomyopathy and liver transplantation. *Liver Transpl* 2000;6(Suppl 1):s44-s52.

9. Liu H, Song D, Lee SS. Cirrhotic cardiomyopathy. *Gastroenterol Clin Biol* 2002;**26**:842-847.
10. Gaskari SA, Honar H, Lee SS. Therapy insight: cirrhotic cardiomyopathy. *Nat Clin Pract Gastroenterol Hepatol* 2006;**3**:329-337.
11. Cazzaniga M, Salerno F, Pagnozzi G, et al. Diastolic dysfunction is associated with poor survival in cirrhotic patients with transjugular intrahepatic portosystemic shunt. *Gut* 2007;**56**:869-875.
12. Nagueh SF, Middleton KJ, Kopelen HA, Zoghbi WA, Quinones MA. Doppler tissue imaging: a noninvasive technique for evaluation of left ventricular relaxation and estimation of filling pressures. *J Am Coll Cardiol* 1997;**30**:1527-1533.
13. Chobanian AV, Bakris GL, Black HR, et al. Seventh report of the Joint National Committee on prevention, detection and treatment of high blood pressure. *Hypertension* 2003;**42**:1206-1252.
14. Nagueh SF, Appleton CP, Gillebert TC, et al. Recommendations for the evaluation of left ventricular diastolic dysfunction by echocardiography. *J Am Soc Echocardiogr* 2009;**22**:107-133.
15. Palka P, Lange A, Sutherland GR. Doppler tissue imaging myocardial wall motion velocities in normal subjects. *J Am Soc Ecocardiogr* 1995;**8**:659-668.
16. Henery WL, Demaria A, Gramiak R. Report of The American Society of Echocardiography Committee on nomenclature and standarts in 2D echocardiography. *Circulation* 1980;**62**:212-217.
17. Wong F, Lui P, Lilly L, Bomzon A, Blendis L. Role of cardiac structural and functional abnormalities in the pathogenesis of hyperdynamic circulation and renal sodium retention in cirrhosis. *Clin Sci* 1999;**97**:259-267.
18. Finucci G, Desideri A, Sacerdoti D. Left ventricular diastolic function in liver cirrhosis. *Scand J Gastroenterol* 1996;**31**:279-284.
19. Valeriano V, Funaro S, Lionetti R, Riggio O, Pulcinelli G, Fiore P. Modification of cardiac function in cirrhotic patients with and without ascites. *Am J Gastroenterol* 2000;**95**:3200-3205.
20. Pozzi M, Carugo S, Boari G, et al. Evidence of functional and structural cardiac abnormalities in cirrhosis patients with or without ascites. *Hepatology* 1997;**26**:1131-1137.
21. Salerno F, Cazzaniga M, Pagnozzi G, et al. Humoral and cardiac effects of TIPS in cirrhotic patients different "effective" blood volume. *Hepatology* 2003;**38**:1370-1377.
22. Arbol LR, Achecar L, Serradilla R, et al. Diastolic dysfunction is a predictor of poor outcomes in patients with cirrhosis, portal hypertension and a normal creatinine. *Hepatology* 2013;**58**:1732-1741.
23. Papastergiou V, Skorda L, Lisgos P, et al. Ultrasonographic prevalence and factors predicting left ventricular diastolic dysfunction in patients with liver cirrhosis: Is there a correlation between the grade of diastolic dysfunction and the grade of liver disease? *Scientific World Journal* 2012;**2012**: 615057.
24. Kelbaek H, Eriksen J, Brynjolf I, et al. Cardiac performance in patients with asymptomatic alcoholic cirrhosis of the liver. *Am J Cardiol* 1984;**54**:852-855.
25. Grose RD, Nolan J, Dillon JF, et al. Exercise-induced left ventricular dysfunction in alcoholic and non-alcoholic cirrhosis. *J Hepatol* 1995;**22**:326-332.
26. Wong F, Girgrah N, Graba J, Allidina Y, Liu P, Blendis L. The cardiac response to exercise in cirrhosis. *Gut* 2001;**49**:268-275.
27. Lengyel M, Nagy A, Zorándi A. Tissue Doppler echocardiography: a new technique to assess diastolic function. *Orv Hetil* 2002;**143**:333-339.