

Effectiveness of infliximab in the treatment of perianal fistulas in ulcerative colitis: report of two cases

Patricia Ramírez de la Piscina, Ileana Duca, Silvia Estrada, Katerina Spicakova, Rosario Calderón, Leire Urtasun, Carlos Marra-López^a, Marta Salvador^a, Elvira Delgado^a, Francisco García Campos^a

Hospital Universitario de Álava (HUA)-Sede Txagorritxu, Universidad del País Vasco, Vitoria-Gasteiz, Spain

Abstract

Ulcerative colitis is a chronic inflammatory bowel disease of unknown etiopathogenesis and increasing incidence in recent years. Perianal complications of ulcerative colitis are rare and seem to be associated with higher extent of inflammation and a more severe course of the disease. The cases of two male patients with severe corticoid-dependent ulcerative colitis of protracted clinical course who developed perianal fistulas and abscesses successfully treated with infliximab are reported. Treatment with infliximab was followed by perianal fistula closure with marked improvement in the quality of life over 2-year follow-up period.

Keywords Ulcerative colitis, perianal fistulas, Infliximab

Ann Gastroenterol 2013; 26 (1): 1-3

Introduction

Ulcerative colitis is a chronic inflammatory bowel disease of unknown pathogenesis, characterized by mucosal ulceration, rectal bleeding, diarrhea and abdominal pain. Perianal complications are less frequent than in patients with Crohn's disease. In a review of the Mayo Clinic of local complications in 2000 patients with ulcerative colitis, fistulizing disease was recorded in approximately 2% of patients, with rectovaginal fistulas being more frequent than perianal fistulas [1]. In a recent case-control study, concomitant perianal disease was observed in 5% of patients with ulcerative colitis, being more frequent among men with extensive disease [2]. Although perianal problems are rarely life threatening, they are associated with a decrease in quality of life and represent an important aspect in the care of patients with ulcerative colitis. Also, fistulas in patients with ulcerative colitis are associated with severe disease and high rate of complications after ileal pouch anal anastomosis [3].

Tumor necrosis factor (TNF)- α is a key proinflammatory cytokine overexpressed in patients with ulcerative colitis.

Service of Gastroenterology, Hospital Universitario de Álava (HUA)-Sede Txagorritxu, Universidad del País Vasco, Vitoria-Gasteiz, Spain

Conflicts of Interest: None

Correspondence to: Patricia Ramírez de la Piscina, Service of Gastroenterology, Hospital Txagorritxu, C/ José Achótegui s/n, E-01009 Vitoria-Gasteiz, Spain, Tel.: +34 9450 07301, Fax: +34 9450 07359, e-mail: PATRICIA.RAMIREZDELAPISCINAURRACA@osakidetza.net

Received 28 August 2012; accepted 9 October 2012

Infliximab, a chimeric IgG1 monoclonal antibody, binds with high affinity to TNF- α , neutralizing its biologic activity. There is evidence that in patients with moderate to severe ulcerative colitis whose disease is refractory to conventional treatment, infliximab is effective in inducing clinical remission, clinical response, promoting mucosal healing and reducing the need for colectomy at least in the short term [4-6]. Infliximab has been shown to be effective in the treatment of fistulizing disease in patients with Crohn's disease [7] but little is known about the effectiveness of infliximab for inducing closure of perianal fistula and maintaining this response in patients with ulcerative colitis.

We report two cases of perianal fistulas in patients with severe corticoid-dependent ulcerative colitis successfully treated with infliximab.

Case reports

A 52-year-old male never-smoker presented at the age of 40 years with a moderate episode of left-sided ulcerative colitis, with endoscopic and histological confirmation. Several endoscopies were done, showing that from the rectum to 55 cm of the anal edge, the mucosa was inflamed with purulent exudates, loss of vascular pattern and multiple continuous small ulcerations. It also showed a diffuse, uniformly fine granularity and friability with erythematous-hemorrhagic appearance. No small intestine involvement was demonstrated either by the ileocolonoscopy or magnetic resonance imaging (MRI) scan.

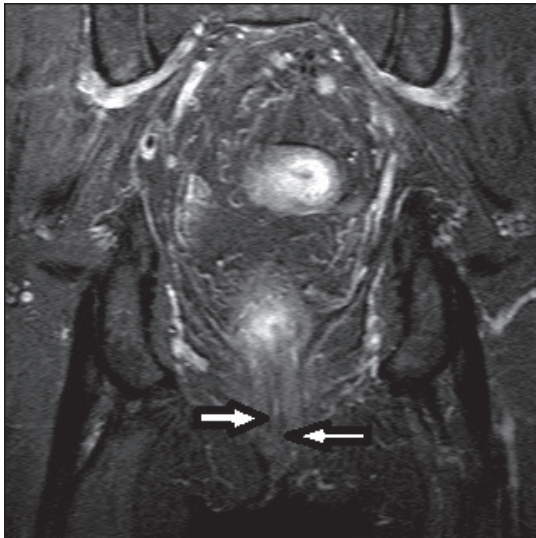


Figure 1 Coronal STIR sequence showing the fistulous track (arrows) with hyperintense fluid content

He was successfully controlled with full doses of i.v. corticosteroids and oral and topical 5-aminosalicylic acid. During the clinical course, the patient was admitted to the hospital on several occasions because of episodes of moderate-to-severe corticoid-dependent ulcerative colitis. Quality of life was impaired after the onset of azathioprine (2.5 mg/kg/day) and clinical-endoscopic remission was achieved for 4 years. Later he presented almost three mild-moderate relapses, necessitating the administration of corticosteroids. Six years after diagnosis he was readmitted to hospital with fever (38.7°C), bloody diarrhea and mucus (8 to 10 bowel movements daily) and perianal pain. On physical examination, pallor and diffuse abdominal pain were noted. Laboratory tests disclosed serum hemoglobin 10.8 g/dL, leukocyte count 15,000 cells/mm³, platelet count 515,000 cells/mm³, serum C-reactive protein (CRP) 141.3 mg/dL and serological study of p-ANCA was positive. Pelvic MRI scan showed various perianal abscesses and two extra-sphincteric fistulous tracks. Surgical debridement and seton placement was performed. After an initial improvement, the patient was readmitted 5 months later because of a new episode of ulcerative colitis and reappearance of perianal fistulas. Treatment with infliximab, 5 mg/kg given as an induction dose at 0, 2 and 6 weeks (as done in perianal fistulas of Crohn's disease) with maintenance doses every two months was followed by prompt clinical improvement in ulcerative colitis and complete closure of perianal fistulas. At present after a follow up of 2 years, with Infliximab treatment, no further relapse has occurred.

A 43-year-old male never-smoker was diagnosed endoscopically and histologically for ulcerative sigmoiditis at the age of 40 years. The histological findings showed fragments of colonic mucosa with an intense and acute inflammatory cell infiltrate (presence of polymorphonuclear neutrophils) in the lamina propria, with formation of cryptitis. There was also mucin

depletion but no granulomas were seen. He presented with a severe episode of bloody diarrhea (12 to 15 bowel movements daily), pallor, abdominal pain and serum hemoglobin of 10.7 g/dL, leukocyte count 11,000 cells/mm³, platelet count 531,000 cells/mm³, serum CRP 134.6 mg/dL and serological p-ANCA was negative. He was treated with full doses of i.v. corticosteroids and oral and topical 5-aminosalicylic acid. One year later, he was readmitted to hospital because of fever (38°C) and perianal discomfort. The MRI scan showed inflammatory changes in the mucosa of the entire colon (without small intestine involvement), the presence of an inter-sphincteric fistulous track and a perianal abscess (Fig. 1). A good response was initially obtained after surgical debridement of the abscess and seton placement. Over the next years, he was admitted to the hospital for several episodes of moderate-to-severe ulcerative colitis and treatment with azathioprine was indicated. Despite immunosuppressive treatment, the perianal fistulizing disease did not improve and anti-TNF therapy was indicated. Infliximab was started at 5 mg/kg as an induction dose (at 0, 2 and 6 weeks) followed by maintenance doses every two months. Complete response and closure of the perianal fistula was achieved. At present, after a follow up of 2 years, recurrence of neither ulcerative colitis nor perianal disease has been observed.

Discussion

Perianal disease associated with ulcerative colitis was initially described in the 1950s and 1960s and different reports have documented a high prevalence of such problems in patients with ulcerative colitis [1,8,9]. Overall, these early studies suggested that the rate of perianal complications in patients with ulcerative colitis ranged between 20% and 25% [3] but these rates were misleading because many patients with presumed ulcerative colitis may in fact have Crohn's disease or indeterminate colitis. In our cases, the diagnosis of ulcerative colitis was thoroughly and repeatedly documented, as several endoscopies and corresponding histological studies were done. The diagnosis of Crohn's disease was ruled out after no small intestine involvement was observed in ileocolonoscopy and MRI scan. The serological study of p-ANCA was variable in our patients (one positive and the other negative), ASCA study was not done, but as many reports have documented, both p-ANCA and ASCA do not play an important role in the differential diagnosis of Crohn's colitis and ulcerative colitis in adults, as they have variable sensitivity and specificity.

The incidence of perianal fistula in this study was 0.9% [10]. The incidence of perianal fistulas in patients with ulcerative colitis in our hospital is approximately 0.5-1% and both cases were diagnosed in male patients.

It is postulated that perianal fistulas develop as a result of chronic inflammation of the rectal wall, with subacute perforation, abscess formation and then fistulizing disease. Also, perianal fistulizing disease has been correlated with a more severe clinical course of ulcerative colitis and extent of

the disease [3]. The patients herein reported had severe and extensive ulcerative colitis characterized by a protracted clinical course and corticosteroid dependence. Surgical treatment of fistulizing disease was unsuccessful as complete closure of the fistulous track was not achieved.

In these two patients with ulcerative colitis and perianal disease, treatment with infliximab was effective not only for inducing closure of the perianal fistula but also for maintaining this response for as long as 2 years. These cases add up to evidence of the effectiveness of infliximab in treating the underlying inflammatory condition as measured by mucosal healing and permanent fistula closure. Therefore, these clinical observations support the clinical benefits of infliximab for permanent closure of fistula-in-ano in patients with severe steroid-dependent ulcerative colitis complicated by perianal fistulizing disease.

References

1. Sloan WP, Bargen JA, Baggrenstoss, AM. Local complications of chronic ulcerative colitis based on the study of 2000 cases. *Mayo Clin Proc* 1950;**25**:240-244.

2. Zabana Y, Van Domselaar M, Garcia-Planella E, et al. Perianal disease in patients with ulcerative colitis: a case-control study. *J Crohns Colitis* 2011;**5**:338-341.
3. Hamzaoglu I, Hodin RA. Perianal problems in patients with ulcerative colitis. *Inflamm Bowel Dis* 2005;**11**:856-859.
4. Rutgeerts P, Sandborn WJ, Feagan BG, et al. Infliximab for induction and maintenance therapy for ulcerative colitis. *N Engl J Med* 2005;**353**:2462-2476.
5. Sandborn WJ, Rutgeerts P, Feagan BG, et al. Colectomy rate comparison after treatment of ulcerative colitis with placebo or infliximab. *Gastroenterology* 2009;**137**:1250-1260.
6. Sandborn WJ. Mucosal healing with infliximab: results from the Active Ulcerative Colitis Trials. *Gastroenterol Hepatol* 2012;**8**:117-119.
7. Present DH, Rutgeerts P, Targan S, et al. Infliximab for the treatment of fistulas in patients with Crohn's disease. *N Engl J Med* 1999;**340**:1398-1405.
8. Dombal FT, Watts JM, Watkinson G, Goligher JC. Incidence and management of anorectal abscess, fistula and fissure, in patients with ulcerative colitis. *Dis Colon Rectum* 1966;**9**:201-206.
9. Edwards F, Truelove SC. The course and prognosis of ulcerative colitis. Part III. Complications. *Gut* 1964;**32**:1-22.
10. Richard CS, Cohen Z, Stern HS, McLeod RS. Outcome of the pelvic pouch procedure in patients with prior perianal disease. *Dis Colon Rectum* 1997;**40**:647-652.