

Gastroenteropancreatic neuroendocrine tumors: diagnosis and treatment

Marc Díez, Alexandre Teulé, Ramon Salazar

Institut Català d'Oncologia, L'Hospitalet del Llobregat, Barcelona, Spain

Abstract

Gastroenteropancreatic neuroendocrine tumors (GEP-NETs) are relatively rare and complex neoplasms that present many clinical challenges. Most GEP-NETs are sporadic, but they can be multiple and a component of a familial syndrome. Assessment of the location and extent of GEP-NETs is crucial for management and a number of novel imaging modalities are under evaluation with the principal goal of increasing sensitivity for the detection of micro-metastases while retaining specificity. The appropriate diagnosis and treatment of neuroendocrine tumors often involves collaboration between specialists in multiple disciplines, using specific biochemical, radiologic, and surgical methods. Management strategies include surgery, radiological intervention, cytotoxic chemotherapies, somatostatin analogs and novel biological agents such as sunitinib and everolimus. Other biological agents, new chemotherapy regimens and somatostatin-tagged radionuclide therapies are also under investigation. In spite of this, comparison between therapeutic modalities is currently difficult. Further studies are warranted to individualize and optimize the diagnosis and treatment of these tumors.

Keywords gastroenteropancreatic neuroendocrine tumors, targeted drugs, PET, everolimus, sunitinib

Ann Gastroenterol 2012; 25 (4): 1-8

Introduction

Gastroenteropancreatic neuroendocrine tumors (GEP-NETs), also known as carcinoids and islet cell tumors, are tumors derived from neuroendocrine cells that can occur anywhere along the gastrointestinal tract and comprise a heterogeneous family of neoplasms with a wide and complex spectrum of clinical behavior. These tumors have been considered rare diseases, although the most recent data from the US Surveillance Epidemiology and End Results show an impressive increase of more than 400% in the incidence of this disease over a period of 29 years, rising from 1.09 per 100,000 population in 1973 to 5.25 per 100,000 population in 2004 [1]. GEP-NETs are more prevalent than many other tumors of the gastrointestinal tract, including stomach and pancreatic carcinomas combined. Age at diagnosis is generally younger than for carcinomas (5th decade) and they may

arise sporadically or as a result of hereditary predisposition syndromes such as multiple endocrine neoplasia type 1, Von Hippel-Lindau's disease or neurofibromatosis type 1.

GEP-NETs have traditionally been divided into foregut (esophagus, stomach, proximal duodenum, liver and pancreas), midgut (distal duodenum ileum, jejunum, ascending colon and proximal two thirds of transverse colon) and hindgut tumors (distal third of transverse colon, descending colon, sigmoid colon and rectum).

Survival of patients with GEP-NETs depends on stage and histology. Patients with well- and moderately-differentiated distant metastases have a 5-year survival probability of 35%; conversely, in patients with poorly-differentiated distant metastases, the 5-year survival probability drops to only 4% [1].

Treatment has two objectives: 1) remove the tumor, or, alternatively, reduce or stop the growth and spread of it; and 2) relieve symptoms of excessive hormone production.

Diagnosis

GEP-NETs are characterized by their ability to produce, store and secrete a large number of peptide hormones and biogenic amines which can lead to the development of distinct clinical syndromes. Based on this, GEP-NETs are broadly subdivided into "functional" or "non-functional" tumors (with or without a clinical syndrome attributable to

Medical Oncology Department, Institut Català d'Oncologia, L'Hospitalet del Llobregat, Barcelona, Spain

Conflict of Interest: None

Correspondence to: Ramon Salazar, Medical Oncology Department, Medical Oncology Department, Av Gran Via s/n km 2.7 08907 L'Hospitalet de Llobregat Spain, Fax +34 93 260 77 41; e-mail: ramonsalazar@iconcologia.net

Received 19 April 2012; accepted 19 June 2012

Table 1 Classification of GEP-NETs by site of origin and by hormonal activity

GEP-NET	Secretion product	Clinical symptoms/ syndrome
Functional carcinoid	Serotonin	Carcinoid syndrome (flushing, diarrhea and heart disease)
Gastrinoma	Gastrin	Zollinger–Ellison syndrome (acid hypersecretion, duodenal ulceration, esophagitis and diarrhea)
Insulinoma	Insulin	Hypoglycemia
Glucagonoma	Glucagon	Diabetes and necrolytic migratory erythema
VIPoma	VIP	Verner-Morrison or WDHA syndrome (watery diarrhea-hypokalemiachlorhydria)

GEPNETs, gastroenteropancreatic neuroendocrine tumors; VIP, vasoactive intestinal peptide

hormonal hypersecretion, respectively). Most GEP-NETs do not secrete biologically active substances and present fairly late with symptoms of mass effects or distant metastases [2]. Among the “functional” tumors, each of these secreted substances causes a specific clinical syndrome, including carcinoid, Zollinger–Ellison, insulinoma, Verner–Morrison, and glucagonoma syndromes (Table 1). Specific markers for these syndromes are basal and/or stimulated levels of urinary 5-hydroxyindoleacetic acid, serum or plasma gastrin, insulin, vasoactive intestinal polypeptide and glucagon, respectively. General markers such as chromogranin A, pancreatic polypeptide, serum neuron-specific enolase and subunit of glycoprotein hormones have been used for screening purposes in patients without distinct clinical hormone-related syndromes. The most important general circulating tumor marker is chromogranin A, expressed in 80–90% of all patients with GEP-NETs. Chromogranin A determination is also useful for staging, prognosis and follow up, since the serum concentration correlates to the tumor mass.

Tumor location and extent have a decisive role in therapy planning. Imaging modalities include conventional radiology, such as transabdominal ultrasonography, computerized tomography (CT) and magnetic resonance imaging, selective angiography, nuclear imaging including somatostatin receptor (SSTR) scintigraphy with single-photon emission CT, bone scintigraphy, endoscopic ultrasonography and various intraoperative methods. For localization of both primary and metastatic lesions, the primary imaging method should be somatostatin receptor scintigraphy (Octreoscan), a test where [¹¹¹In]indium-labeled somatostatin analogs, such as octreotide, are used in scintigraphy for detecting tumors expressing somatostatin receptors. However, none of these techniques have 100% sensitivity. Currently, several new modalities to increase sensitivity are under evaluation [3]. Positron emission tomography (PET) with 18-fluorodeoxyglucose ([¹⁸F] FDG) is mainly useful for highly aggressive GEP-NETs [4]. For this reason, other hybrid systems of diagnosis are under evaluation. Among these, PET with (68)Ga-DOTATATE or (68)Ga-DOTATOC, both with a high affinity to the SSTR subtype 2 [5], enables diagnosis of NET with a very high sensitivity, but they are not widely available.

Staging

There are three major classifications in current clinical use: 1) the WHO classification [6,7]; 2) the European NET Society (ENETS) TNM and grading system [8,9]; and 3) the Union for International Cancer Control (UICC) TNM system (7th edition, 2010) [10] (Tables 2 and 3).

In 2000, the WHO published a classification, which was updated in 2004 and most recently in 2010, differentiating between the terms NET and neuroendocrine carcinoma (Table 4). The grading system is based upon the number of mitoses (low [G1]: <2/10 HPF; intermediate [G2]: 2–10/10HPF; high [G3]: >10/HPF) and the ki-67 index ($\leq 2\%$, 3–20%, > 20% for the G1, G2, G3 tumors, respectively). GEP-NETs were divided into well-differentiated NETs (<2 cm in size, <2% Ki-67 index), well-differentiated neuroendocrine carcinomas (>2 cm in size, >2% Ki-67 index, or angioinvasive), and poorly-differentiated neuroendocrine carcinomas (Ki-67 >20%). Later the ENETS defined two different guidelines covering this issue for foregut NETs first and for midgut and hindgut NETs later on. Finally, in 2010 the UICC published another TNM system. Both the WHO classification and the TNM staging system seem to be of prognostic value, and both of them have their own advantages and disadvantages.

Table 2 TNM classification of NETs

GI tract:
– Carcinoid: separate staging by site
– Small cell/large cell: stage as carcinoma
Pancreas: stage as carcinoma
Lung: stage as carcinoma
Skin: separate classification for Merkel cell carcinoma

Adapted from Sobin L, Gospodarowicz M, Wittekind C (eds) (2010) TNM classification of malignant tumours, 7th edn. Wiley-Blackwell, Oxford

Table 3 TNM staging for gastrointestinal NETs

Appendix	Stomach
T1 ≤2 cm	Tis <0.5 mm confined to mucosa
T2 >2–4 cm; cecum	T1 Lamina propria or submucosa & ≤1 cm
T3 >4 cm; ileum	T2 Muscularis propria or >1 cm
T4 Perforates peritoneum; other organs, structures	T3 Subserosa
	T4 Perforates serosa; adjacent structures
Small intestine	Large intestine
T1 Lamina propria/submucosa and ≤1 cm	T1 Lamina propria or submucosa or ≤2 cm; T1a ≤1 cm; T1b 1–2 cm
T2 Muscularis propria or >1 cm	T2 Muscularis propria or >2 cm
T3 Jejunal, ileal: subserosa. Ampullary, duodenal: pancreas or retroperitoneum	T3 Subserosa or pericorectal tissues
T4 Perforates serosa; adjacent structures	T4 Perforates serosa; adjacent structures
Carcinoid: appendix	Carcinoid: other GI sites
Stage I T1 N0	Stage I T1 N0
Stage II T2, T3 N0	Stage IIA T2 N0
Stage III T4 N0	Stage IIB T3 N0
Any T N1	Stage IIIA T4 N0
Stage IV Any T Any N M1	Stage IIIB Any T N1
	Stage IV Any T Any M M1

Adapted from Sobin L, Gospodarowicz M, Wittekind C (eds) (2010) *TNM classification of malignant tumours, 7th edn*. Wiley-Blackwell, Oxford

Therapy

Surgery

Surgery is the only potentially curative therapeutic strategy in localized disease. Radical oncological surgery is indicated except for small carcinoids (<2 cm) of the stomach, appendix or rectum, in which more conservative surgical or endoscopic resections may be appropriate due to their low malignant potential. Small pancreatic insulinomas also have a very good prognosis (90% are benign tumors) and tumor enucleation is generally sufficient [3]. No adjuvant therapy is recommended in completely resected, well-differentiated localized GEP-NETs. Adjuvant chemotherapy with platinum and etoposide may be

considered in poorly-differentiated tumors.

Surgery also plays a major role in advance disease. Surgery of metastatic disease is recommended if complete resection is feasible. Major cytoreductive therapy with palliative purposes may be considered even if R0 is not achievable in patients with extensive liver metastasis and hormonal syndrome refractory to medical therapy. Prophylactic cholecystectomy to prevent cholelithiasis is recommended in patients undergoing surgery if treatment with somatostatin analogs is anticipated. Surgery of the primary tumor may be performed in selected patients to avoid obstruction due to the neoplasm or to the fibrotic reaction commonly associated with small-bowel carcinoids.

When a functioning tumor is diagnosed before surgery, there is a risk of carcinoid crisis when the tumor is operated.

Table 4 Comparison of the WHO classifications of gastroenteropancreatic neuroendocrine neoplasms

WHO 2000	WHO 2010
Highly differentiated neuroendocrine tumor	Neuroendocrine tumor G1 (carcinoid) and G2
Highly differentiated neuroendocrine carcinoma	
Poorly differentiated (small-cell) neuroendocrine carcinoma	(Small- or large-cell) neuroendocrine carcinoma G3
Mixed endocrine-exocrine carcinoma	Mixed adenoneuroendocrine carcinoma
Tumor-like lesion	Hyperplastic and preneoplastic lesion

This should be prevented by the administration of continuous i.v. octreotide at a dose of 50 mg/h for 12 h prior to and at least 48 h after surgery [11]. Boluses of 100-200 mg octreotide can be given as required. It is also important to avoid drugs that release histamine or activate the sympathetic nervous system [12]. Similarly, prophylaxis with glucose infusion for insulinoma surgery, proton pump inhibitor and octreotide for gastrinomas may be required.

Interventional radiology

In patients not suitable candidates for surgery, regional control of liver metastases may be achieved by different ablative techniques such as radiofrequency ablation, laser ablation and cryotherapy, among others [3].

Reduction in tumor burden often leads to a reduction in hormone secretion and, consequently, an improvement in symptom control.

Other locoregional approaches include embolization of the hepatic artery by particles or cytotoxic agents (chemoembolization). These therapeutic strategies are based on the fact that, unlike normal hepatocytes, NET liver metastases are preferentially supplied by arterial rather than portal blood. They are generally employed with palliative purposes in patients with slow growing functional tumors refractory to medical therapy, but may also be useful to reduce tumor burden and control tumor progression in non-functioning tumors. Doxorubicin (DOX), streptozocin (STZ), mitomycin and fluorouracil (5-FU) are commonly used agents in this context, although randomized studies that properly evaluate the benefit-risk ratio of chemoembolization with that of mechanical embolization are lacking. Clinical responses have been reported in up to 80% of the patients and radiological responses in about 50%. Median duration of response extends up to 18 months [13]. Common adverse events include pain, fever or elevation of liver enzymes. Severe complications occur in 10% of cases and include acute liver or renal failure, liver abscess, cholecystitis or carcinoid crisis.

Although these results have documented the beneficial effects of hepatic arterial embolization (HAE) and chemoembolization (HACE), doubt remains whether chemoembolization offers any therapeutic advantage over particulate embolization alone. In a retrospective study of Gupta *et al* [14], the addition of intraarterial chemotherapy to embolization did not improve the overall survival (OS) or progression-free survival (PFS) in patients with carcinoid tumors. In contrast, a tendency toward prolonged survival (31.5 vs. 18.2 months) and improved response rate (50% vs. 25%) was noted in patients with islet cell carcinomas who received HACE compared with patients who received HAE, although the differences did not reach statistical significance. They hypothesized that it is not unreasonable to expect that intraarterial chemotherapy will be more effective in patients with islet cell carcinomas, because carcinoid tumors are generally resistant to systemic chemotherapy, whereas islet cell carcinomas generally demonstrate a better response. In

another retrospective review at three institutions by Pitt *et al* [15] OS was similar in patients managed by HACE or HAE.

Liver transplantation

Unlike other types of tumors, due to the slow growth of NET, the possibility of liver transplantation exists. A small group of patients with bilobar liver metastases without extrahepatic disease can be considered for total tumor hepatectomy with liver transplantation in two situations: 1) with the intent to cure; or 2) to palliate from life-threatening hormonal disturbances [16]. In most series, a high rate of recurrence was reported, with a 5-year survival not exceeding series without liver transplantation and high morbidity and mortality. Survival is better with metastatic small intestinal NETs compared with metastatic pancreatic NETs (pNETs). Patients <50 years of age, with low expression of Ki-67 and E-cadherin, are most likely to benefit [17].

Somatostatin analogs

The foundation of current NET therapy is based on the long-acting somatostatin analogs. They act to alleviate symptoms in carcinoid syndrome, stabilize tumor growth and improve quality of life.

There are at least five subtypes of the somatostatin receptor (sst1-5), a G-protein-coupled membrane receptor to which native somatostatin peptides bind to with high affinity. SSTRs, predominantly sst5, are present in the majority of NETs (70-95%) but in only half of insulinomas and less in poorly-differentiated NETs and somatostatinomas. As a result of ligand activation, there is inhibition of the release of many hormones and impairment of hormonally-mediated exocrine function. By this mechanism, somatostatin analogs prevent spontaneous and provoked flushing and secretory diarrhea in patients with carcinoid syndrome.

The elimination half-life of natural somatostatin peptides is only a few minutes, which necessitated the need for a synthetic agent, octreotide, with a half-life of several hours, and a high affinity for sst2 and sst5. It is administered by s.c. injection or i.v. infusion with s.c. dosing starting at 50-100 µg b.i.d. or t.i.d. to a maximum daily dose of 3000 µg. Other short-acting somatostatin analogs include lanreotide. In a prospective crossover study, no differences in symptom control or biochemical response were seen between octreotide and lanreotide [18]. Short-acting somatostatin analogs are used in testing patient tolerability, immediate relief of carcinoid syndrome symptoms and stabilization of symptoms for 10-14 days before converting to long-acting therapy [19]. It is also used in rescue therapy when carcinoid syndrome symptoms occur despite long-acting analogs and also perioperatively to prevent and treat carcinoid crises by either s.c. or i.v. routes. Nevertheless, the mainstay of NET therapy is in the form of long-acting somatostatin analogs. The development of long-acting depot formulations, octreotide LAR and lanreotide

Autogel, has allowed clinically practical administration of these drugs by i.m. and deep s.c. routes every 28 days. Biochemical response rates with an inhibition of hormone production are seen in 30-70% with symptom control in the majority of patients [20,21]. Escalation of dose is often required over time for symptom control due to poorly understood 'tachyphylaxis'. Minor differences may exist between long-acting octreotide and long-acting lanreotide but it has been demonstrated that tumors refractory to one analog may respond to the treatment of another [22].

Recently, it has been confirmed that somatostatin analogs have a role in non-functioning small intestinal tumors. Data derived from the PROMID phase III study has shown that long-term administration of octreotide LAR inhibits tumor growth in midgut NETs with low-volume metastatic disease, with time to progression twice as long as the placebo arm [23].

Few side effects have been reported with somatostatin analogs and these include fat malabsorption, gallstones, gall bladder dysfunction, vitamins A and D malabsorption, headaches, diarrhea, dizziness and hypo- and hyperglycemia.

Interferon- α (IFN- α)

IFN- α was introduced as a treatment for GEP-NETs in the early 1980s and exerts an anti-proliferation and anti-secretory effect. Apart from inhibiting tumor cell cycle progression, it has anti-angiogenic properties. The usual dose is 3-5 million units s.c., three to five times a week. Symptomatic and biochemical responses have been noted in 50% of patients with disease stabilization in 60-80% at a follow up of 4 years. However, significant tumor reduction only occurs in 10-15% [24]. Limitations in use of IFN include its side effects that include flu-like symptoms, bone marrow suppression, thyroid disorders, psychiatric phenomena and chronic fatigue syndrome. It has been suggested that patients not responding to either somatostatin analogs or IFN- α alone may show an improved response with inhibition of tumor growth and prolonged survival with the combination treatment of those two agents. However, prospective, randomized trials have not demonstrated any benefit [25].

Peptide-receptor radionuclide therapy (PRRT)

Patients with advanced disease and a positive octreoscan may be considered for PRRT. The optimal radionuclide is still to be determined, but treatment with ^{90}Y trium octreotide (^{90}Y DOTATOC), ^{90}Y -lanreotide and ^{177}Lu -DOTA octreotate have been reported to achieve not only tumor stabilization but also tumor regression (objective partial responses) in up to 30% of GEP-NETs [26]. However, experience is limited to single-institution selected series and randomized controlled trials are lacking. In addition, the nonavailability of this therapeutic strategy in most countries further limits its widespread use. The appropriate timing of this therapeutic intervention or

the relative long-term benefit-risk ratio compared to other treatment options are key questions that remain unanswered. Alternatively, ^{131}I iodine-metaiodobenzylguanidine (MIBG) therapy may be considered in advanced tumors with a positive MIBG scan (20-50% of NETs).

Chemotherapy

Systemic chemotherapy is widely used, but its precise role is not known due to studies including various grades, sites and inconsistent response criteria. Thus, there is no standard regimen. Systemic chemotherapy has been the standard treatment for pNETs based on the data from Moertel *et al* [27] with an objective response of 69%. This study used one of the first combinations with STZ and 5-FU. This group also demonstrated that the combination of STZ and DOX may be better than STZ/FU with a major response rate of 69 vs. 45%, respectively, but this was not confirmed in later studies, which demonstrates problems with comparing studies. The main indication for STZ, 5-FU or DOX includes well-differentiated malignant pancreatic NETs. STZ-based combinations in pancreatic NETs may help control symptoms and achieve tumor response in 40%. A recent study combined 5-FU, cisplatin and STZ (FCiSt) in chemo-naïve patients with metastatic or locally-advanced NETs [28]. Response rates were 38% for pancreatic and 25% for non-pancreatic sites with median time to progression 9.1 months and median OS 31.5 months with an acceptable toxicity profile and an advantageous 1-day outpatient administration.

It is difficult to assess whether subgroups of pancreatic NETs respond differentially due to small numbers, inconsistent assessment criteria and variable regimens amongst studies. Response rates treating pancreatic islet cell tumors with 5-FU, STZ and DOX vary between 40 and 70% [29]. However, in another study, none of the 11 patients with gastrinomas responded to STZ/5-FU/DOX whilst four of the nine (44%) patients with other functioning tumors responded according to RECIST criteria [30].

The use of chemotherapy in midgut and hindgut NETs has a much lower response rate, with <20% of patients benefitting, which may only last 6-8 months with STZ/5-FU/DOX, cyclophosphamide regimens [31]. A retrospective analysis found that temozolomide monotherapy achieved radiological response in 14% and stable disease in 53% [32]. It is generally well tolerated with minimal side effects including leukopenia, nausea and abdominal pain. Another more recent retrospective study of temozolomide combined with capecitabine in 30 chemo-naïve pNETs patients reported an objective radiographic response rate of 70% and median PFS of 18 months [33].

Side effects were relatively tolerable, with a grade 3/4 adverse event rate of only 12%.

Poorly-differentiated or anaplastic NETs are more aggressive, and etoposide and cisplatin combinations have been used to induce response rates of over 50% albeit with short median survival rates and significant toxicity [34].

Novel therapies

Tyrosine kinase and angiogenesis inhibitors

The tyrosine kinase receptor family comprises around 20 different classes including platelet-derived growth factor receptors (PDGFRs), c-kit and epidermal growth factor receptor (EGFR). Targeting PDGFR/c-kit, for example, using agents that are used in acute myelogenous leukemia such as imatinib mesylate, has been disappointing. Sunitinib, an oral tyrosine kinase inhibitor with action against all vascular endothelial growth factor (VEGF) receptor (VEGFR), PDGFR, stem cell factor receptor and FMS-like tyrosine kinase-3, has shown some promise in phase II studies [35]. One hundred and seven patients received sunitinib with 16.7% of pancreatic NETs achieving objective response, 68% achieving stable disease; median time to progression 7.7 months in pNETs, 10.2 months in midgut NETs. The recent phase III study of sunitinib versus placebo in slowly progressing pNETs was halted due to an unplanned early analysis showing significant benefit with PFS of 11.4 months with Sunitinib versus 5.5 months with placebo [36].

Sorafenib, a small molecule inhibitor of Raf kinase, VEGFR-2 and PDGFR tyrosine kinase domains, has been explored in metastatic NETs with 10% partial response and 29% minor response in 41 patients. However, 43% in this study developed grade 3-4 toxicity [37].

NETs are highly vascular and express VEGF, a promoter of angiogenesis. A small phase II study looking at octreotide and bevacizumab versus octreotide and PEG-IFN found that 18% in the bevacizumab arm had partial response and 95% PFS at 18 weeks compared with one partial response and 68% PFS at 18 weeks in the IFN arm [38]. A phase II study looking at bevacizumab and temozolomide has also shown promising results [39].

Mammalian target of rapamycin (mTOR) inhibitors

mTOR is a threonine kinase and part of the phosphatidylinositol-3-kinase/AKT/mTOR pathway, which is crucial in regulation of cell survival and proliferation. It also mediates signalling downstream to growth factor receptors including insulin-like growth factor (IGF) receptor and EGFR. It has been shown that mTOR has a role to play in islet cell tumors in patients with tuberous sclerosis as well as in sporadic NETs [40]. Rapamycin and RAD001, inhibitors of mTOR, lead to a decrease in IGF1 and NET cell growth in studies on pancreatic neuroendocrine cell lines (BON-1) [41]. Thirty-six patients with advanced NETs and evidence of progressive disease were treated with the mTOR inhibitor, temsirolimus, as a single agent in a phase II study. Disease stabilization occurred in 58 cases and partial radiological response in two cases (6%) with median time to progression of 6 months [42]. This modest effect was balanced by adverse events such as fatigue, rash and hyperglycemia experienced in a number of patients.

Yao *et al* published the results of RAD001 in Advanced NETs-1 (RADIANT 1), a phase II study evaluating everolimus alone versus everolimus and depot octreotide in patients with advanced pancreatic NET who had progressed on first-line chemotherapy. In the combined treatment arm, 80% achieved stable disease and 4.4% partial response with a median PFS of 16.7 months [43]. In the arm with everolimus alone, partial responses were seen in 9.6% and stable disease in 67.8%; median PFS of 9.7 months. These promising results led to two everolimus trials, RADIANT-2 and RADIANT-3. RADIANT-2 was a randomized, double-blind, placebo-controlled, multicenter, phase III study of octreotide combined with everolimus or placebo in patients with advanced NETs. The RADIANT 2 trial demonstrated an improvement in PFS from 11 months on the placebo arm to 16 months on the active treatment arm.

On central radiologic review, the statistical significance of this trial was borderline ($P = 0.026$) [44]. RADIANT-3 was a randomized, double-blind, placebo-controlled, multicenter phase III study of everolimus plus best supportive care versus placebo and best supportive care in patients with progressive advanced pancreatic NETs. Results from the latter have recently been published and demonstrated a statistically and clinically significant PFS improvement with medians of 11.0 months with RAD001 (everolimus) compared with 4.6 months with placebo [45].

Conclusions

NETs are increasing in incidence. Perhaps in part the increased incidence is due to improvements in diagnostic imaging with detection of smaller lesions in addition to the incidental diagnosis of asymptomatic cases. However, delayed diagnosis is typical (5-7 years on average) mainly in "nonfunctional" GEP-NETs, resulting in excessive morbidity and mortality and increased probability of metastatic disease. Assessment of the location and extent in these heterogeneous tumors is crucial for management and it may also provide prognostic information. Novel hybrid functional tests may improve the diagnosis and extent of GEP-NETs in the near future.

In recent years there has been significant progress in the treatment of these tumors. Recently two targeted agents have been approved by the FDA for the treatment of progressive pNET [46]. Everolimus is an mTOR inhibitor, which inhibits cell growth, proliferation, and angiogenesis. Sunitinib is a multi-kinase inhibitor thought to have an effect in pNET through inhibition of VEGF, which plays a significant role in angiogenesis. Furthermore, several other targeted drugs are under investigation both in carcinoids and pNETs. Thus, the number of therapies against this neoplasms will probably increase in the next years. In this era of expanding treatment options, understanding how to best sequence and combine treatments becomes increasingly important (Fig. 1). Future randomized trials comparing various therapies and evaluating combination or sequential approaches may help

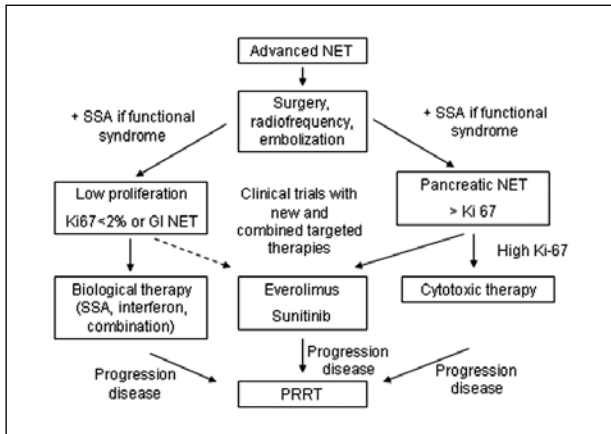


Figure 1 Treatment algorithm in advanced NET (Modified from Pavel M, et al. *Neuroendocrinology* 2012;95:157-176) [47]
PRRT, peptide-receptor radionuclide therapy; SSA, somatostatin analogs

in the development of treatment algorithms. But all this must be accompanied by further studies on the molecular biology of these tumors which also allows us to individualize optimal treatment or sequence of treatment in each case.

References

1. Yao JC, Hassan M, Phan A, et al. One hundred years after "carcinoid": epidemiology of and prognostic factors for neuroendocrine tumors in 35,825 cases in the United States. *J Clin Oncol* 2008;**26**:3063-3072.
2. Garcia-Carbonero R, Capdevila J, Crespo-Herrero G, et al. Incidence, patterns of care and prognostic factors for outcome of gastroenteropancreatic neuroendocrine tumors (GEP-NETs): results from the National Cancer Registry of Spain (RGETNE). *Ann Oncol* 2010;**21**:1794-803.
3. Modlin IM, Oberg K, Chung DC, et al. Gastroenteropancreatic neuroendocrine tumours. *Lancet Oncol* 2008;**9**:61-72.
4. Adams S, Baum R, Rink T, et al. Limited value of fluorine-18 fluorodeoxyglucose positron emission tomography for the imaging of neuroendocrine tumours. *Eur J Nucl Med* 1998;**25**:79-83.
5. Koukouraki S, Strauss LG, Georgoulis V, et al. Evaluation of the pharmacokinetics of 68Ga-DOTATOC in patients with metastatic neuroendocrine tumours scheduled for 90Y-DOTATOC therapy. *Eur J Nucl Med* 2006;**33**:460-466.
6. Kloppel G, Perren A, Heitz PU. The gastroenteropancreatic neuroendocrine cell system and its tumors: the WHO classification. *Ann NY Acad Sci* 2004;**1014**:13-27.
7. Rindi G, Arnold R, Bosman FT. Nomenclature and classification of neuroendocrine neoplasms of the digestive system. In: Bosman FT, Carneiro F, Hruban RH, Theise ND, et al. editors. *WHO classification of tumors of the digestive system*. Lyon: IARC; 2010.
8. Rindi G, Klöppel G, Alhman H, et al. TNM staging of foregut (neuro)endocrine tumors: a consensus proposal including a grading system. *Virchows Arch* 2006;**449**:395-401.
9. Rindi G, Klöppel G, Couvelard A, et al. TNM staging of midgut and hindgut (neuro) endocrine tumors: a consensus proposal including a grading system. *Virchows Arch* 2007;**451**:757-762.
10. Sobin L, Gospodarowicz M, Wittekind C. TNM classification of malignant tumours, 7th edn. Wiley-Blackwell, Oxford 2010.
11. Roy RC, Carter RF, Wright PD. Somatostatin, anaesthesia, and the carcinoid syndrome. Peri-operative administration of a somatostatin analogue to suppress carcinoid tumour activity. *Anaesthesia* 1987;**42**:627-632.
12. Dougherty TB, Cronau LH Jr. Anesthetic implications for surgical patients with endocrine tumors. *Int Anesthesiol Clin* 1998;**36**:31-44.
13. Atwell TD, Charboneau JW, Que FG, et al. Treatment of neuroendocrine cancer metastatic to the liver: the role of ablative techniques. *Cardiovasc Intervent Radiol* 2005;**28**:409-421.
14. Gupta S, Johnson MM, Murthy R, et al. Hepatic arterial embolization and chemoembolization for the treatment of patients with metastatic neuroendocrine tumors: variables affecting response rates and survival. *Cancer* 2005;**104**:1590-1602.
15. Pitt SC, Knuth J, Keily JM, et al. Hepatic neuroendocrine metastases: chemo- or bland embolization? *J Gastrointest Surg* 2008;**12**:1951-1960.
16. Pfitzmann R, Benschmidt B, Langrehr JM, Schumacher G, Neuhaus R, Neuhaus P. Trends and experiences in liver retransplantation over 15 years. *Liver Transpl* 2007;**13**: 248-257.
17. Ahlman H, Friman S, Cahlin C, et al. Liver transplantation for treatment of metastatic neuroendocrine tumors. *Ann N Y Acad Sci* 2004;**1014**:265-269.
18. O'Toole D, Ducreux M, Bommelaer G, et al. Treatment of carcinoid syndrome: a prospective crossover evaluation of lanreotide versus octreotide in terms of efficacy, patient acceptability, and tolerance. *Cancer* 2000;**88**:770-776.
19. Oberg K, Ferone D, Kaltsas G, Knigge UP, Taal B, Plockinger U. ENETS Consensus Guidelines for the Standards of Care in Neuroendocrine Tumors: biotherapy. *Neuroendocrinology* 2009;**90**:209-213.
20. Bajetta E, Procopio G, Catena L, et al. Lanreotide autogel every 6 weeks compared with Lanreotide microparticles every 3 weeks in patients with well differentiated neuroendocrine tumors: a phase III study. *Cancer* 2006;**107**:2474-2481.
21. Toumpanakis C, Garland J, Marelli L, et al. Long-term results of patients with malignant carcinoid syndrome receiving octreotide LAR. *Aliment Pharmacol Ther* 2009;**30**:733-740.
22. Raderer M, Kurtaran A, Scheithauer W, Fiebigler W, Weinlaender G, Oberhuber G. Different response to the long-acting somatostatin analogues lanreotide and octreotide in a patient with a malignant carcinoid. *Oncology* 2001;**60**:141-145.
23. Rinke A, Muller HH, Schade-Brittinger C, et al. Placebo-controlled, double-blind, prospective, randomized study on the effect of octreotide LAR in the control of tumor growth in patients with metastatic neuroendocrine midgut tumors: a report from the PROMID Study Group. *J Clin Oncol* 2009;**27**:4656-4663.
24. Oberg K. Interferon in the management of neuroendocrine GEP-tumors: a review. *Digestion* 2000;**62**(Suppl 1):92-97.
25. Arnold R, Rinke A, Klose KJ, et al. Octreotide versus octreotide plus interferon-alpha in endocrine gastroenteropancreatic tumors: a randomized trial. *Clin Gastroenterol Hepatol* 2005;**3**:761-771.
26. Kwekkeboom DJ, de Herder WW, Kam BL, et al. Treatment with the radiolabeled somatostatin analog [177 Lu-DOTA 0,Tyr3]octreotate: toxicity, efficacy, and survival. *J Clin Oncol* 2008;**26**:2124-2130.
27. Moertel CG, Lefkopoulo M, Lipsitz S, Hahn RG, Klaassen D. Streptozocin-doxorubicin, streptozocin-fluorouracil or chlorozotocin in the treatment of advanced islet-cell carcinoma. *N Engl J Med* 1992;**326**:519-523.
28. Turner NC, Strauss SJ, Sarker D, et al. Chemotherapy with 5-fluorouracil, cisplatin and streptozocin for neuroendocrine tumours. *Br J Cancer* 2010;**102**:1106-1112.
29. Bajetta E, Ferrari L, Procopio G, et al. Efficacy of a chemotherapy combination for the treatment of metastatic neuroendocrine tumours. *Ann Oncol* 2002;**13**:614-621.

30. Kouvaraki MA, Ajani JA, Hoff P, et al. Fluorouracil, doxorubicin, and streptozocin in the treatment of patients with locally advanced and metastatic pancreatic endocrine carcinomas. *J Clin Oncol* 2004;**22**:4762-4771.
31. O'Toole D, Hentic O, Corcos O, Ruzsniwski P. Chemotherapy for gastro-enteropancreatic endocrine tumours. *Neuroendocrinology* 2004;**80**(Suppl 1):79-84.
32. Ekeblad S, Sundin A, Janson ET, et al. Temozolomide as monotherapy is effective in treatment of advanced malignant neuroendocrine tumors. *Clin Cancer Res* 2007;**13**:2986-2991.
33. Strosberg JR, Fine RL, Choi J, et al. First-line chemotherapy with capecitabine and temozolomide in patients with metastatic pancreatic endocrine carcinomas. *Cancer* 2011;**117**:268-275.
34. Mitry E, Baudin E, Ducreux M, et al. Treatment of poorly differentiated neuroendocrine tumours with etoposide and cisplatin. *Br J Cancer* 1999;**81**:1351-1355.
35. Kulke MH, Lenz HJ, Meropol NJ, et al. Activity of sunitinib in patients with advanced neuroendocrine tumors. *J Clin Oncol* 2008;**26**:3403-3410.
36. Raymond E, Dahan L, Raoul JL, et al. Sunitinib malate for the treatment of pancreatic neuroendocrine tumors. *N Engl J Med* 2011;**364**:501-513.
37. Hobday TJ, Rubin J, Holen J, et al. MC044h, a phase II trial of sorafenib in patients (pts) with metastatic neuroendocrine tumors (NET): a Phase II Consortium (P2C) study. *J Clin Oncol* 2007;**25**:4504.
38. Yao JC, Phan A, Hoff PM, et al. Targeting vascular endothelial growth factor in advanced carcinoid tumor: a random assignment phase II study of depot octreotide with bevacizumab and pegylated interferon alpha-2b. *J Clin Oncol* 2008;**26**:1316-1323.
39. Chan JA, Stuart K, Earle CC, et al. Prospective study of bevacizumab plus temozolomide in patients with advanced neuroendocrine tumors. *J Clin Oncol* 2012; DOI:10.1200/JCO.2011.40.3147.
40. Eledrisi MS, Stuart CA, Alshanti M. Insulinoma in a patient with tuberous sclerosis: is there an association? *Endocr Pract* 2002;**8**:109-112.
41. Zitzmann K, De Toni EN, Brand S, et al. The novel mTOR inhibitor RAD001 (everolimus) induces antiproliferative effects in human pancreatic neuroendocrine tumor cells. *Neuroendocrinology* 2007;**85**:54-60.
42. Duran I, Kortmansky J, Singh D, et al. A phase II clinical and pharmacodynamic study of temsirolimus in advanced neuroendocrine carcinomas. *Br J Cancer* 2006;**95**: 1148-1154.
43. Yao JC, Lombard-Bohas C, Baudin E, et al. Daily oral everolimus activity in patients with metastatic pancreatic neuroendocrine tumors after failure of cytotoxic chemotherapy: a phase II trial. *J Clin Oncol* 2010;**28**:69-76.
44. Pavel ME, Hainsworth JD, Baudin E, et al. RADIANT-2 Study Group. Everolimus plus octreotide long-acting repeatable for the treatment of advanced neuroendocrine tumours associated with carcinoid syndrome (RADIANT-2): a randomised, placebo-controlled, phase 3 study. *Lancet* 2011;**378**:2005-2012.
45. Yao JC, Shah MH, Ito T, et al. Everolimus for advanced pancreatic neuroendocrine tumors. *N Engl J Med* 2011;**364**:514-523.
46. Falconi M, Bartsch DK, Eriksson B, et al. Barcelona Consensus Conference participants. ENETS Consensus Guidelines for the management of patients with digestive neuroendocrine neoplasms of the digestive system: well-differentiated pancreatic non-functioning tumors. *Neuroendocrinology* 2012;**95**:120-134.
47. Pavel M, Baudin E, Couvelard A, et al. Barcelona Consensus Conference participants. ENETS Consensus Guidelines for the management of patients with liver and other distant metastases from neuroendocrine neoplasms of foregut, midgut, hindgut, and unknown primary. *Neuroendocrinology* 2012;**95**:157-176.